

Cardiac MRI: Cardiomyopathy

Laura E. Heyneman, MD

**I do not have any relevant financial
relationships with any commercial
interests**

Cardiac MRI: Cardiomyopathy

Laura E. Heyneman, MD

Duke University Medical Center

heyne001@mc.duke.edu

www.radiologytalks.com

Outline

Delayed enhancement

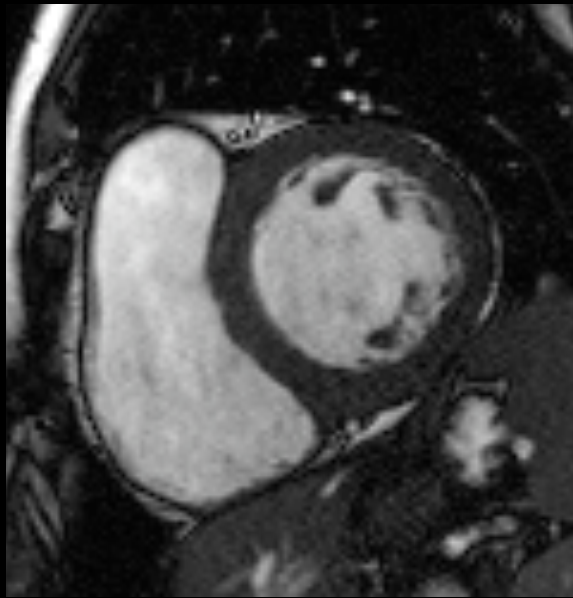
- **patterns**

Specific myopathies:

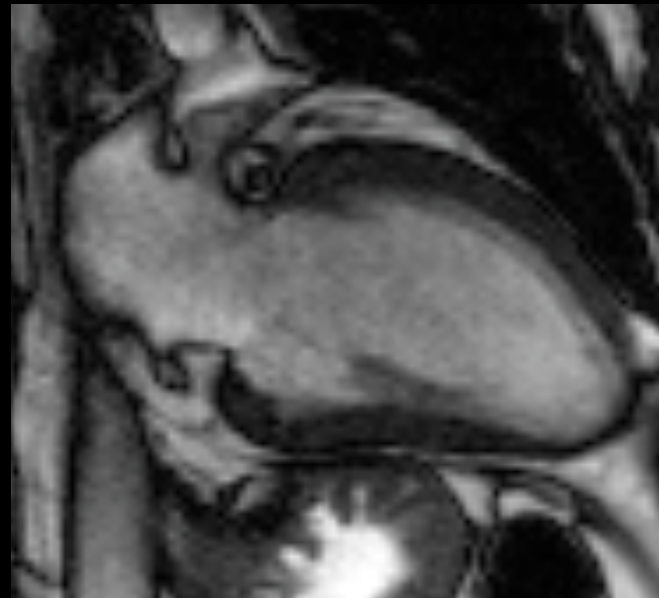
- **dilated CM**
- **sarcoid**
- **hypertrophic**

Cine Imaging

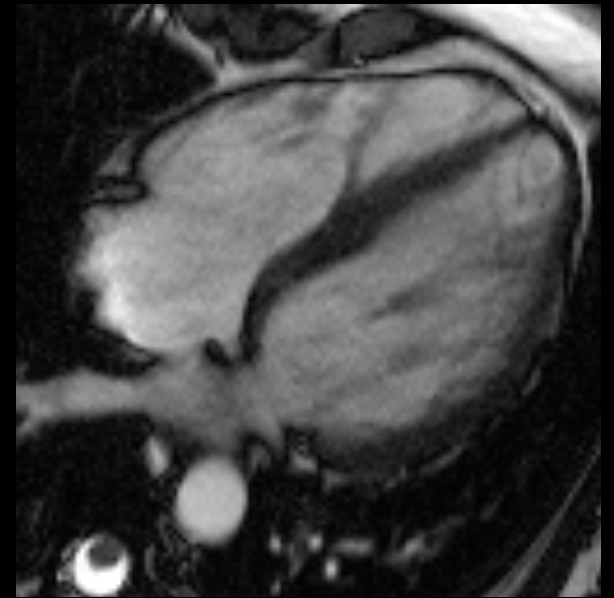Breath held SSFP; real-time
Wall motion, valves



short axis



2 chamber

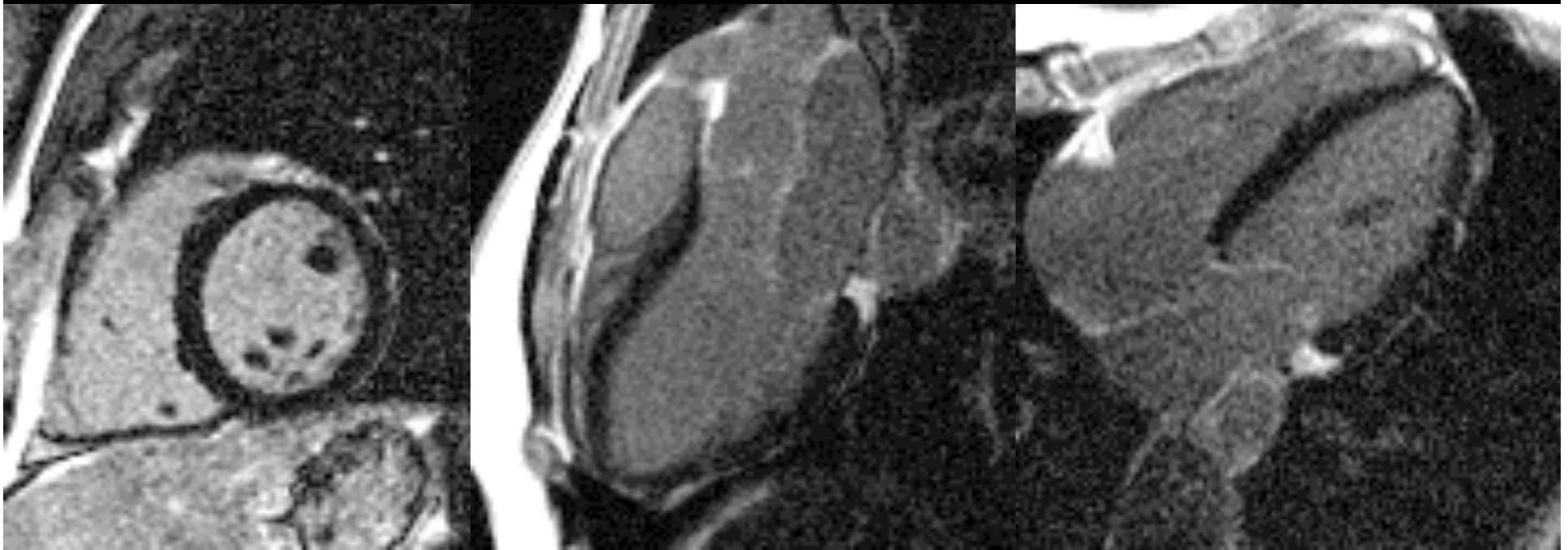


4 chamber

Delayed Enhancement

IR gradient echo

spoiled gradient echo, SSFP



short axis

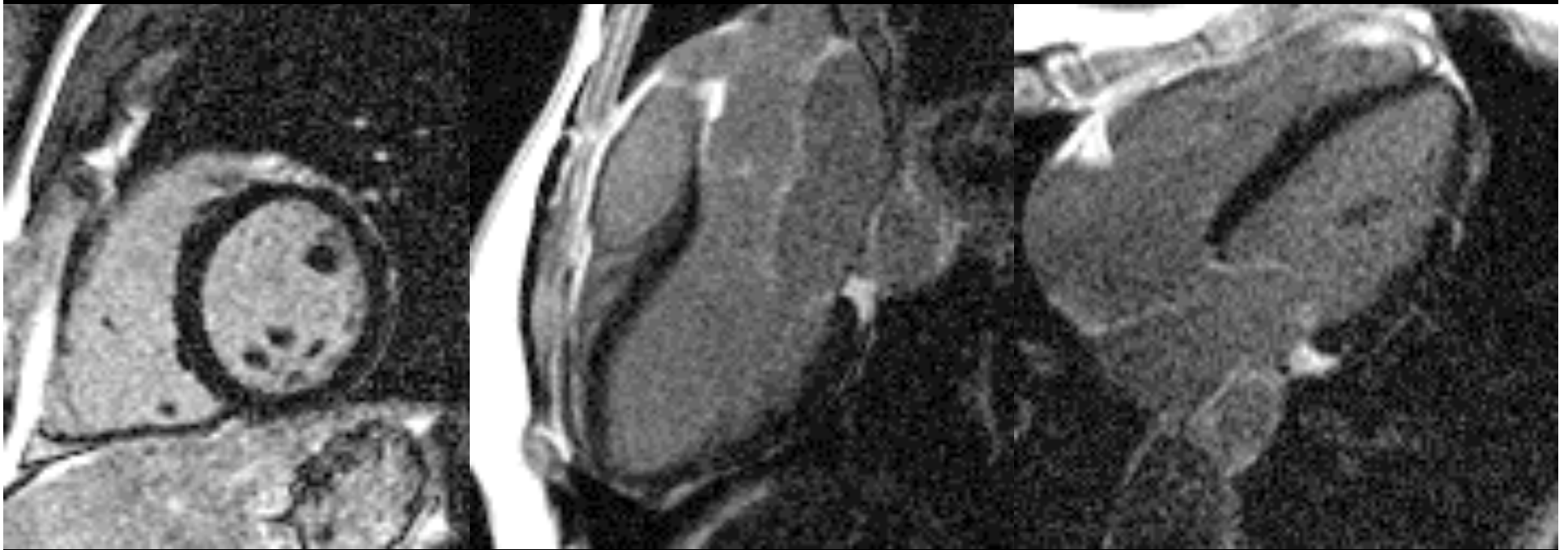
3 chamber

4 chamber

Delayed Enhancement

IR gradient echo

5-15 minutes after IV contrast



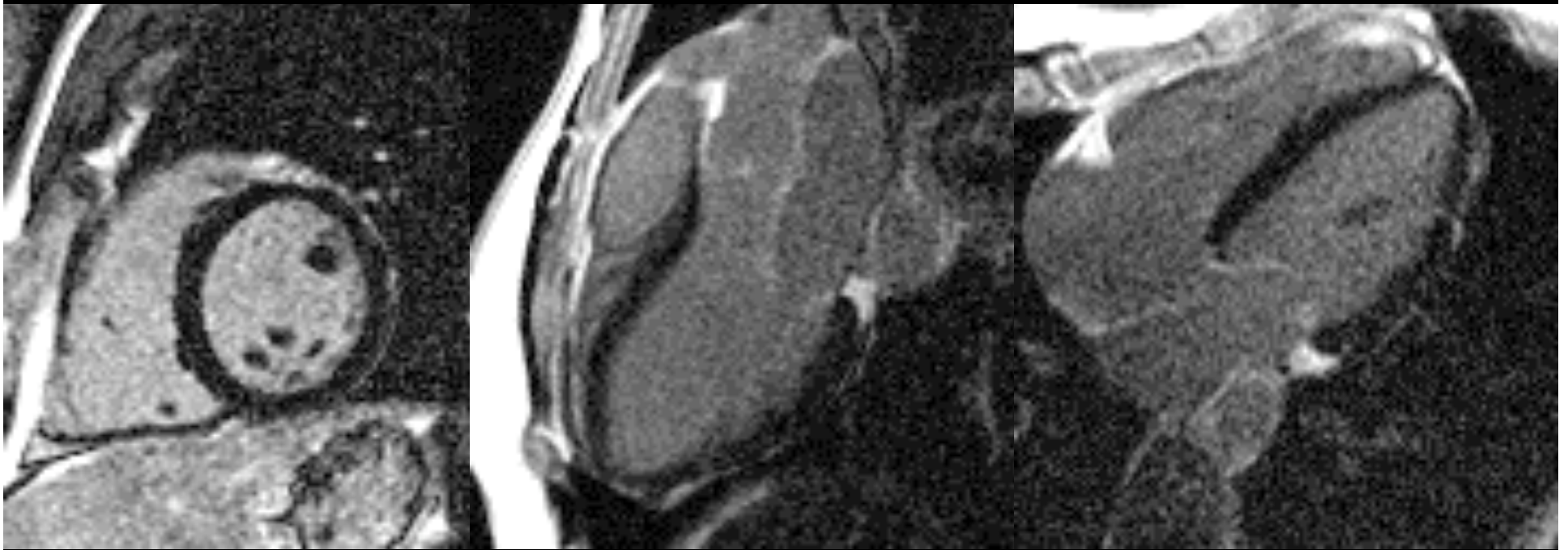
short axis

2 chamber

4 chamber

Delayed Enhancement

Normal myocardium nulled



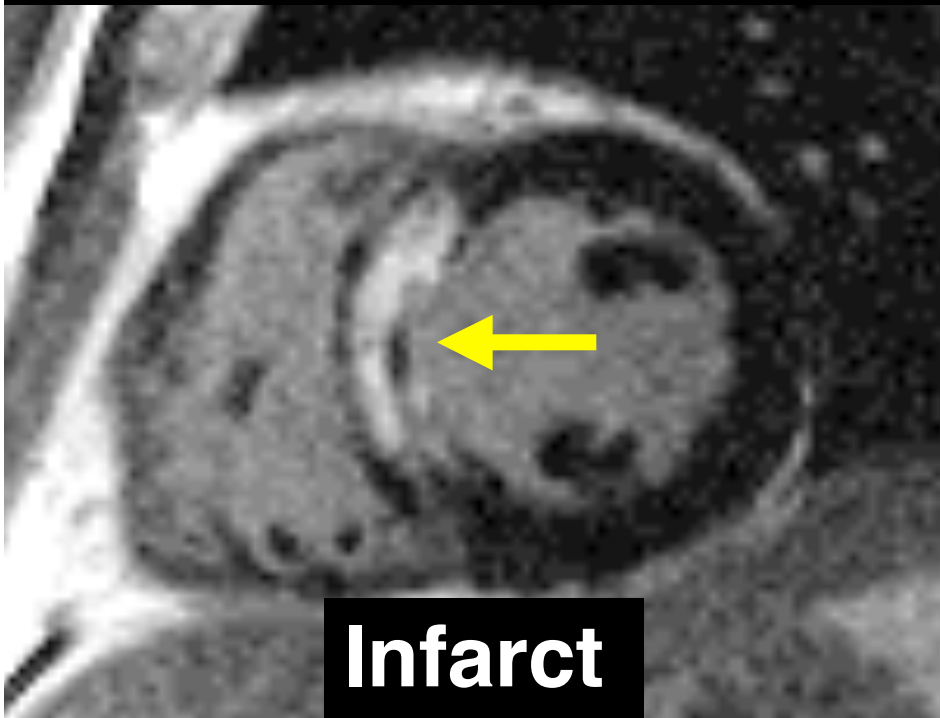
short axis

3 chamber

4 chamber

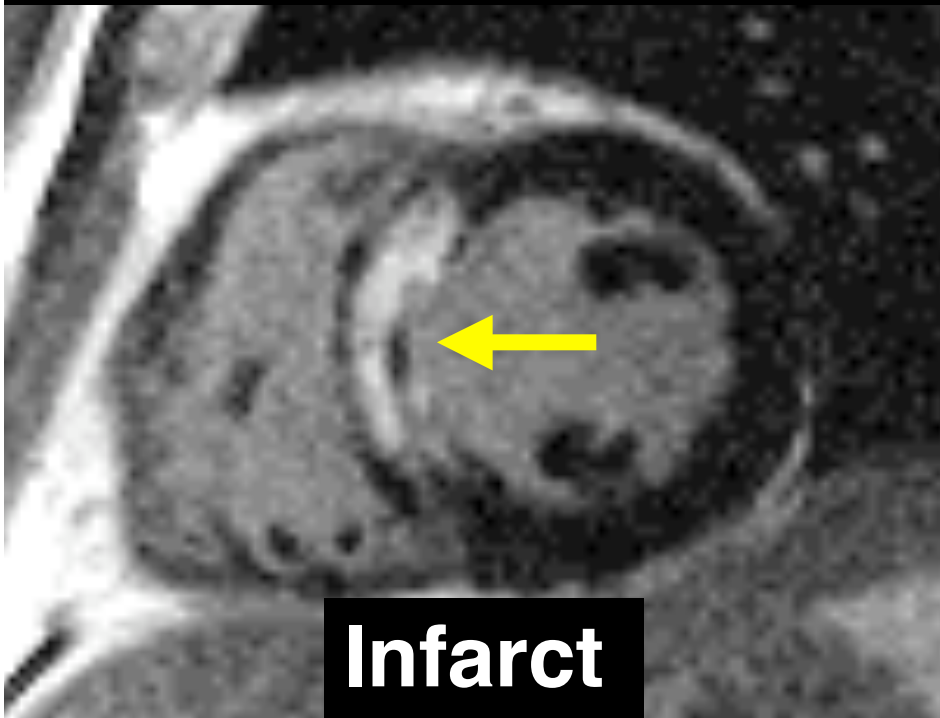
Delayed Enhancement

Delayed enhancement =
abnormal

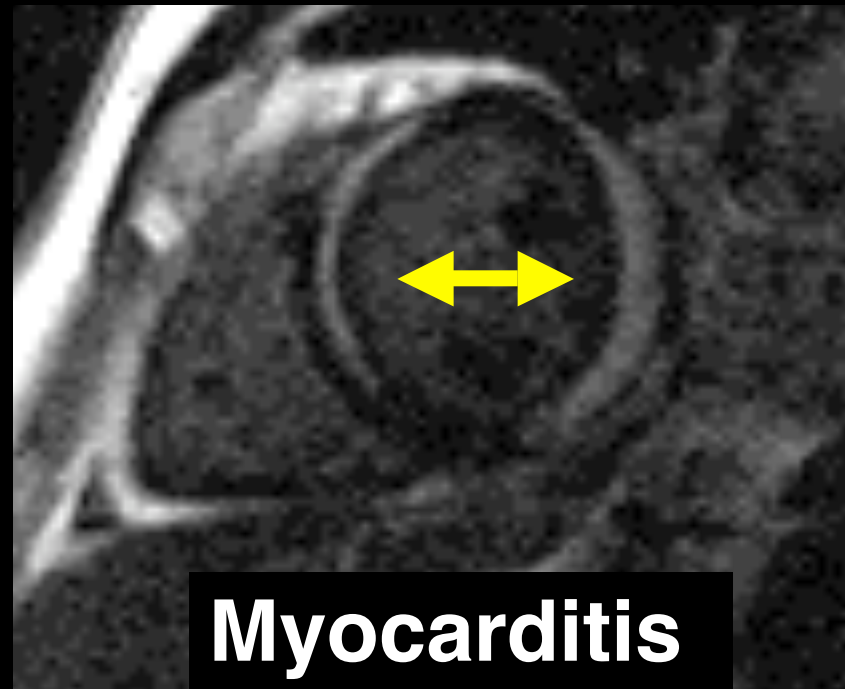


Delayed Enhancement

Delayed enhancement =
abnormal



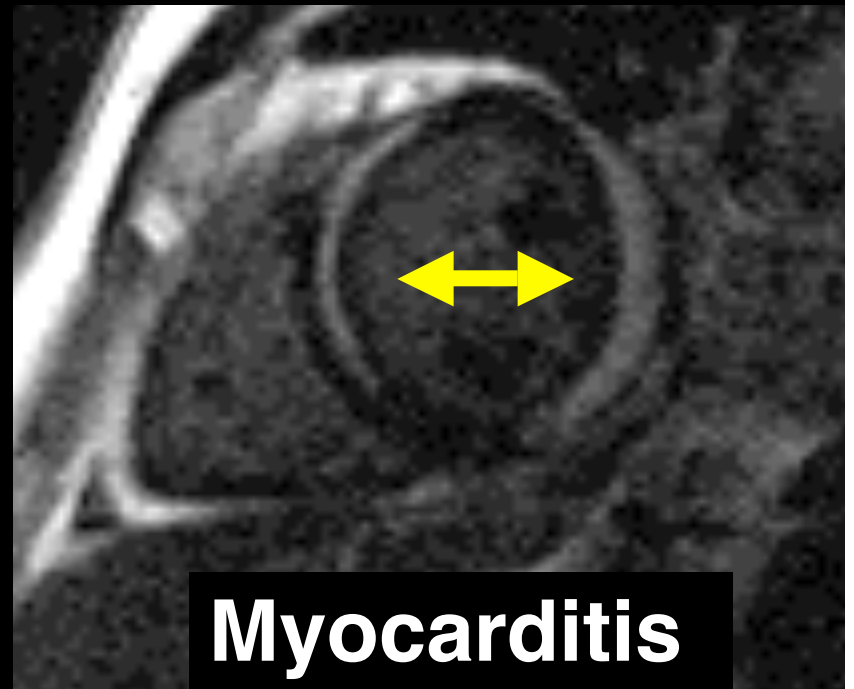
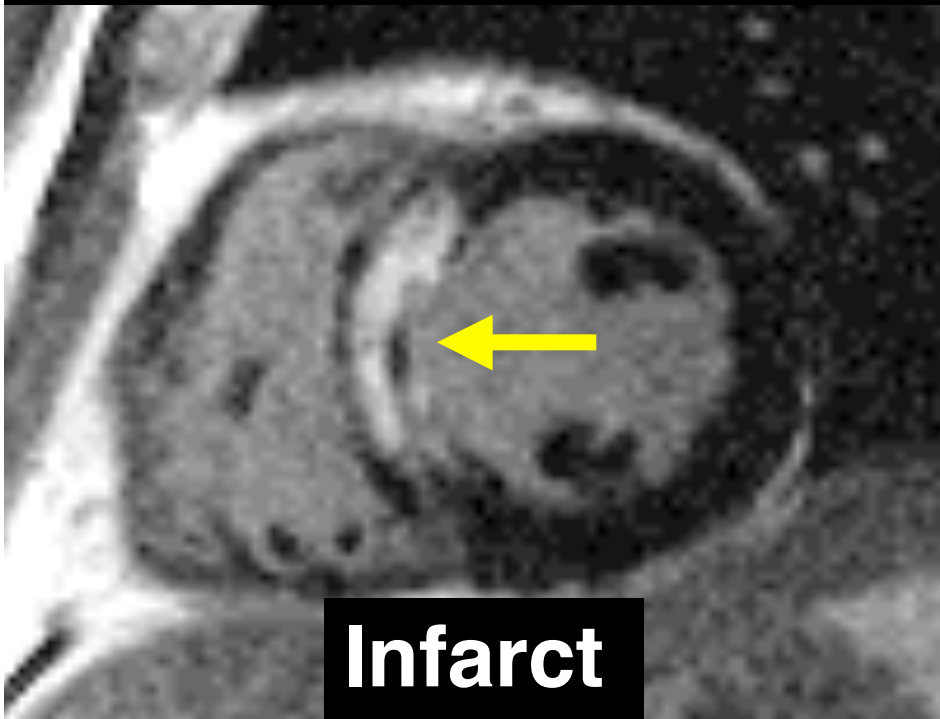
Infarct



Myocarditis

Delayed Enhancement


Is enhancement in an
ischemic pattern?



Cardiol Clin 2007; 25: 71-95

RadioGraphics 2006; 26: 795-810

CAD Enhancement

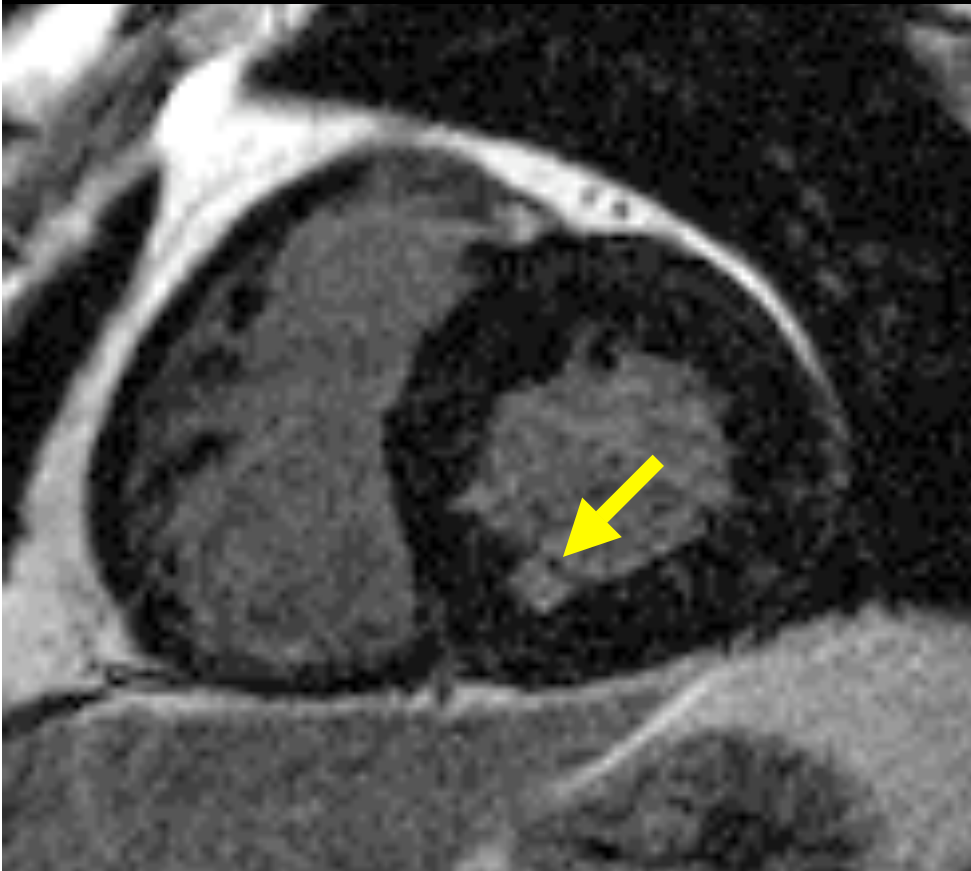


Subendocardial

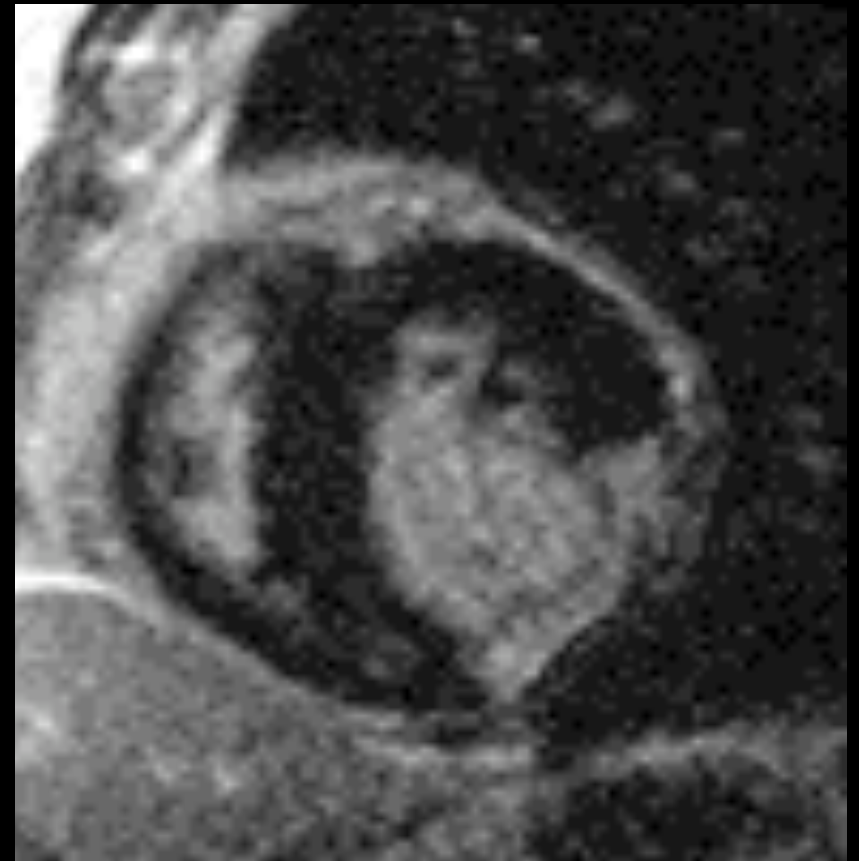

Transmural

CAD Enhancement

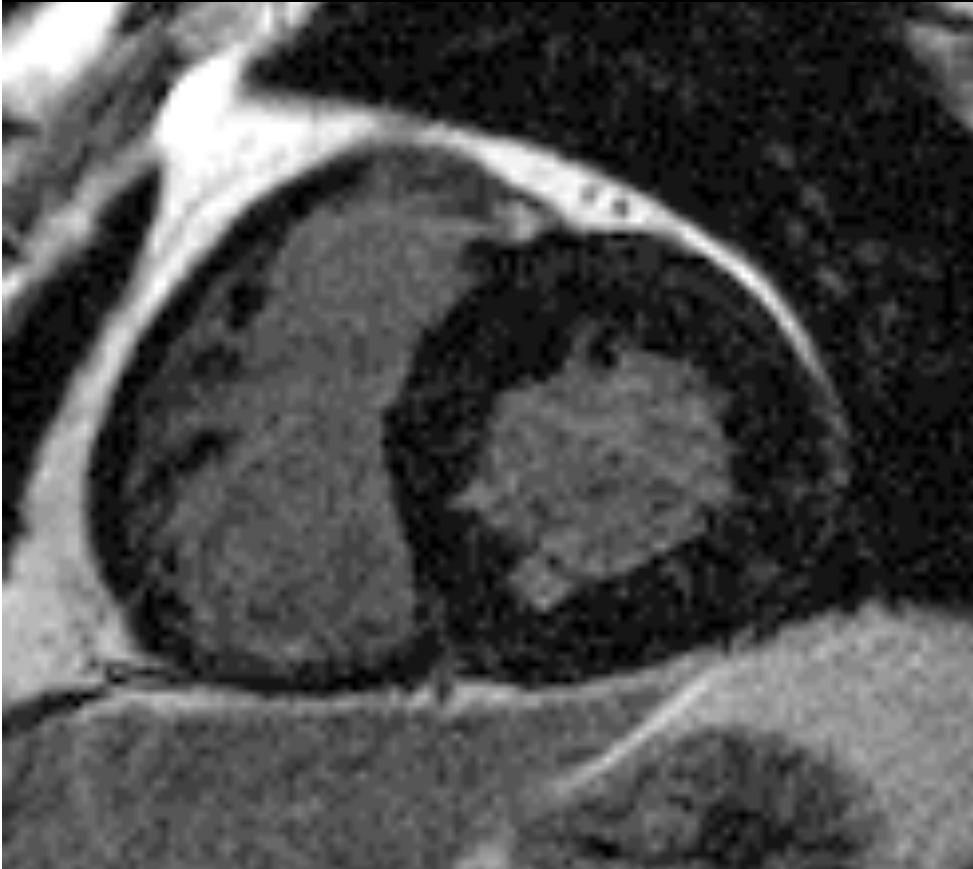


subendocardial

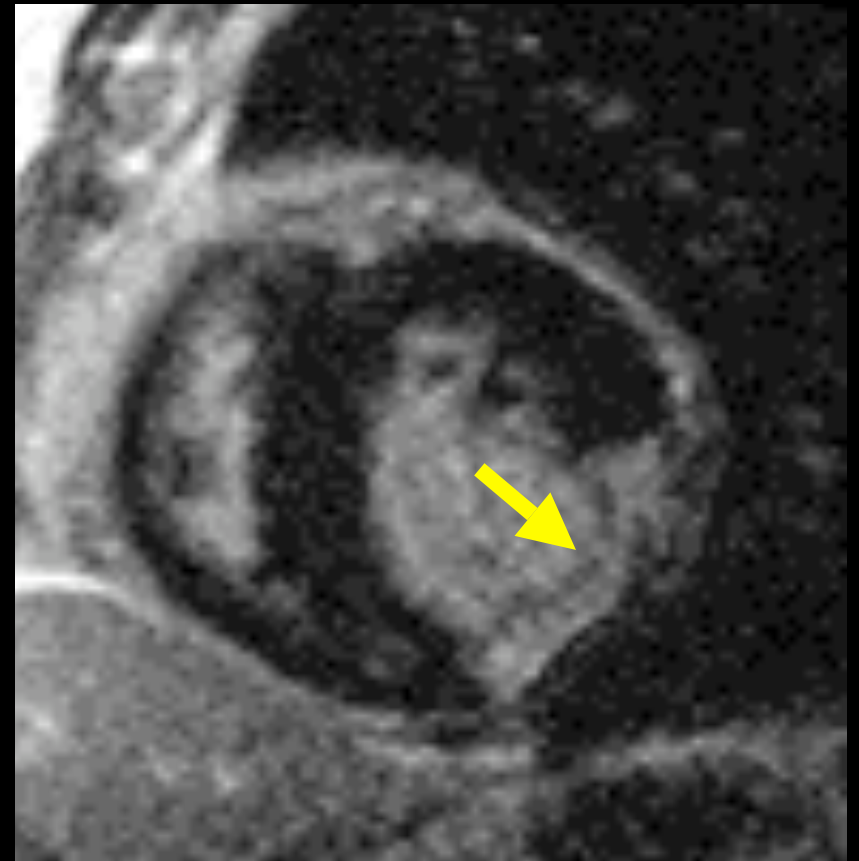

transmural

CAD Enhancement



subendocardial


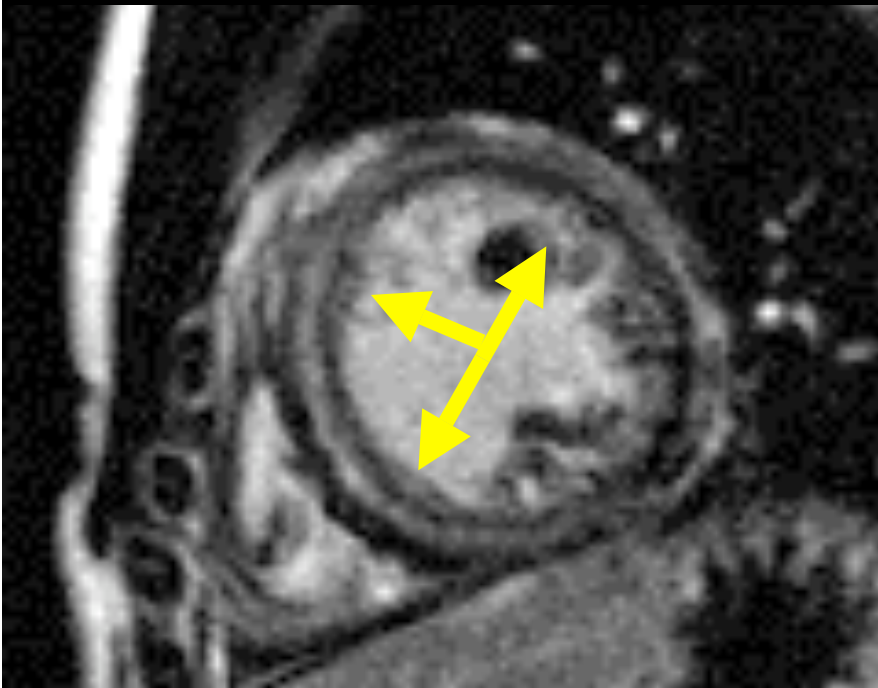


transmural

Enhancement: Non-CAD Patterns

- **Mid-myocardial**
- **Epicardial**
- **RV insertion**
- **Diffuse subendocardial**

Non-CAD Pattern: Midmyocardial



AJR 2005; 184: 1420-1426

Int J Cardiovasc Imaging 2008;24:597-608

Non-CAD Pattern: Midmyocardial


Myocarditis

Hypertrophic

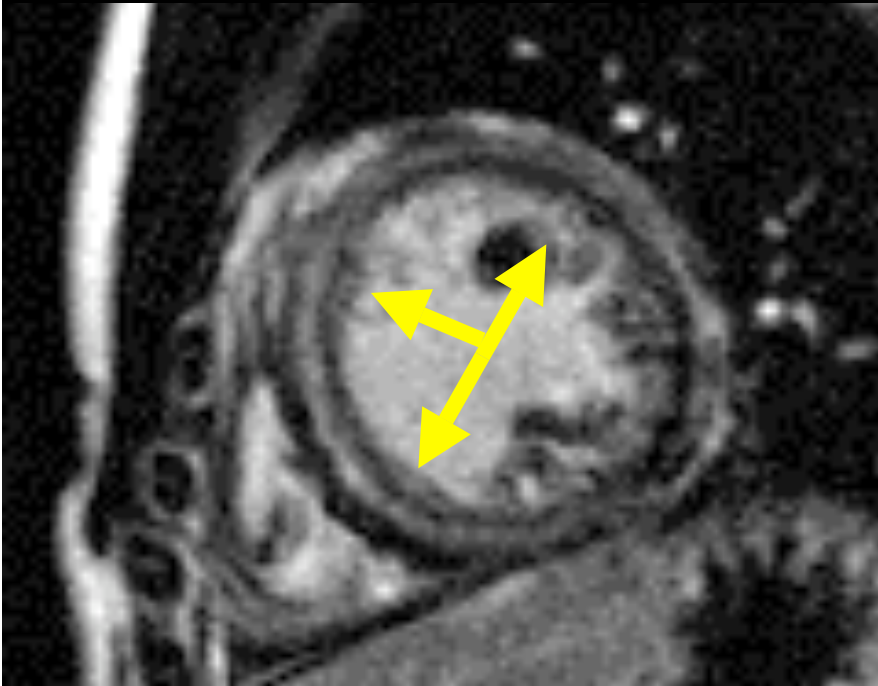
Dilated CM

Sarcoidosis


Chagas disease



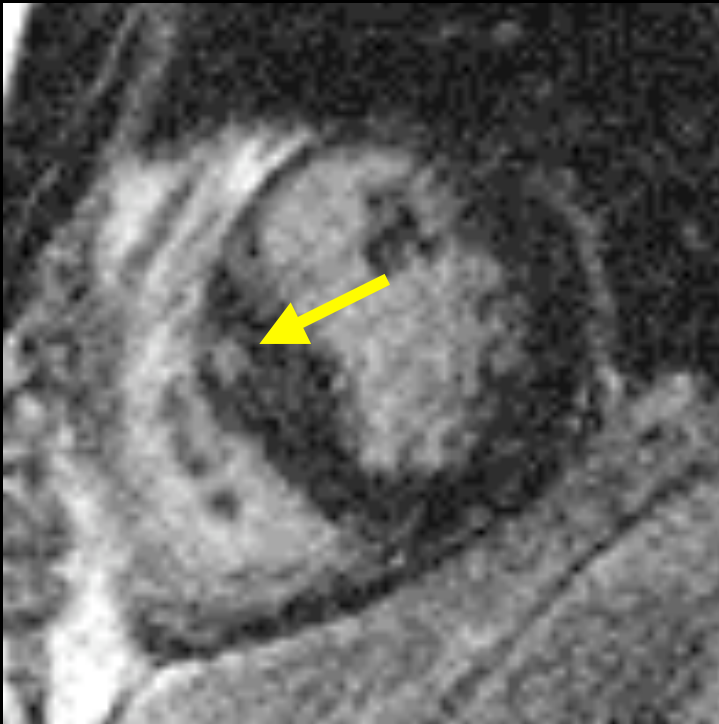Non-CAD Pattern: Midmyocardial




myocarditis




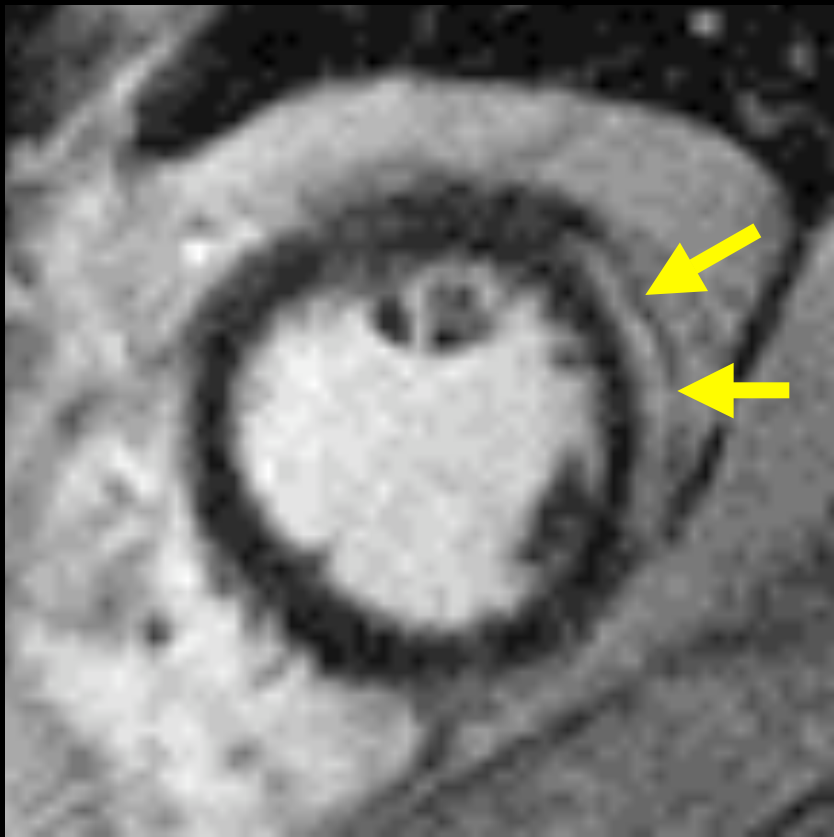
Non-CAD Pattern: Midmyocardial



hypertrophic CM



Non-CAD Pattern: Epicardial




Non-CAD Pattern: Epicardial

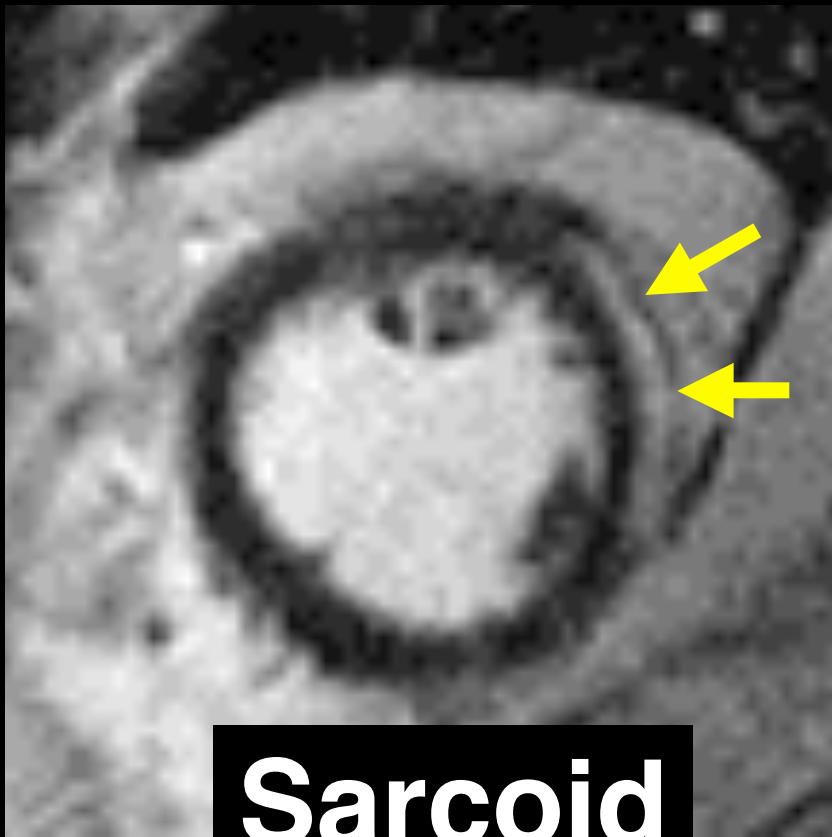
Myocarditis

Sarcoidosis


Chagas disease



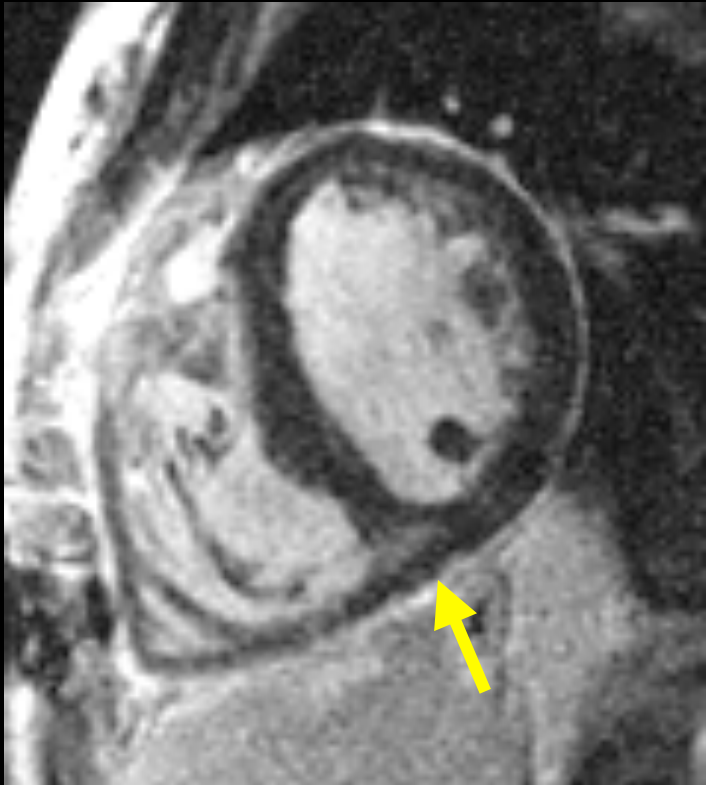
Non-CAD Pattern: Epicardial



Sarcoid



Non-CAD Pattern: RV insertion site




AJR 2005; 184: 1420-1426

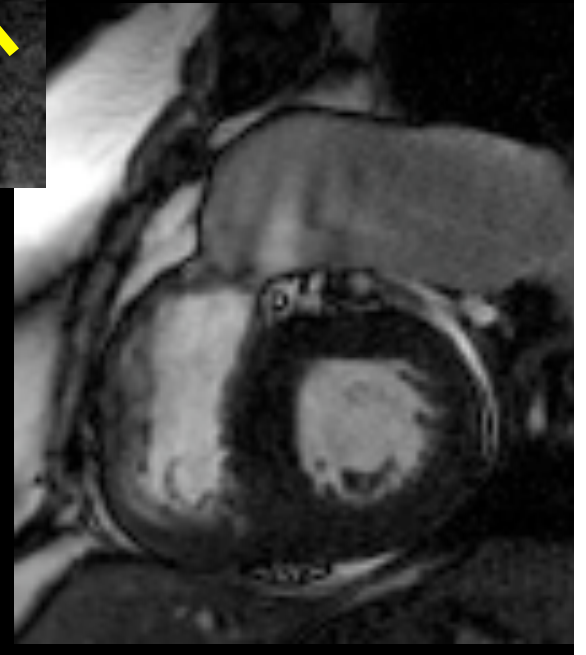
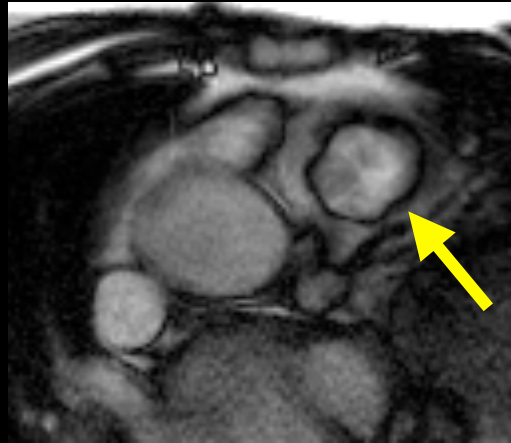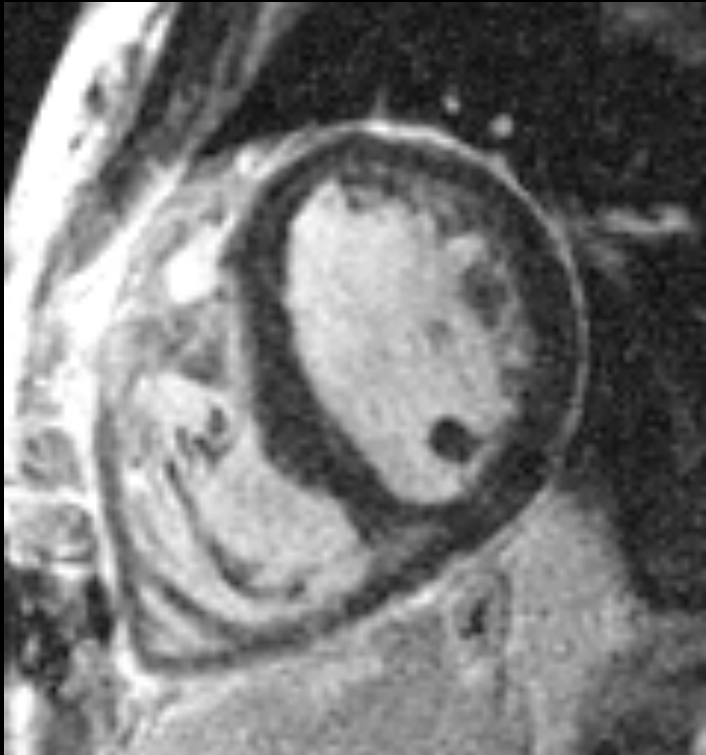Int J Cardiovasc Imaging 2008;24:597-608

Non-CAD Pattern: RV insertion site

RV overload

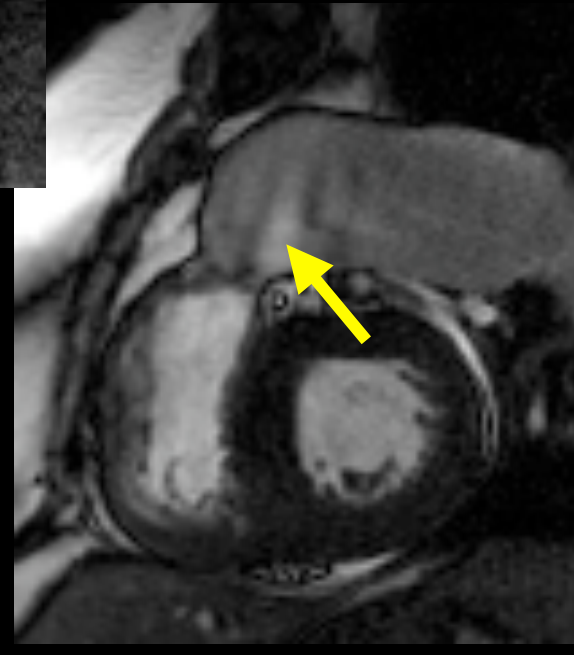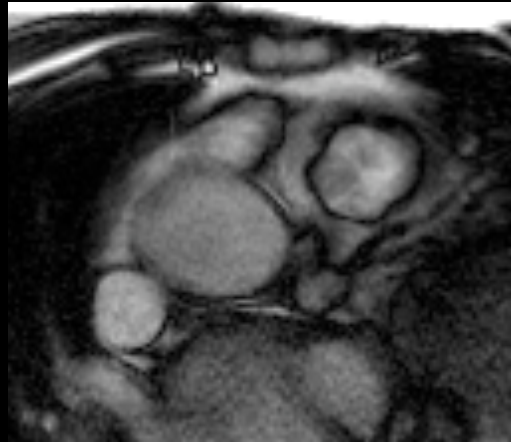


Non-CAD Pattern: RV insertion site



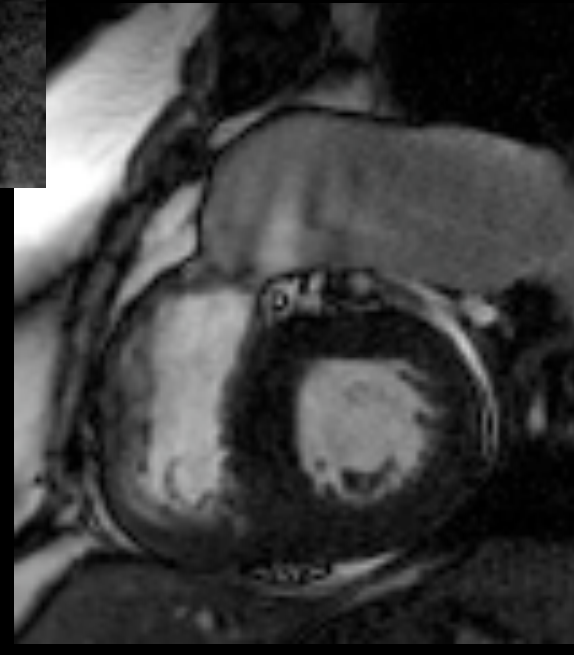
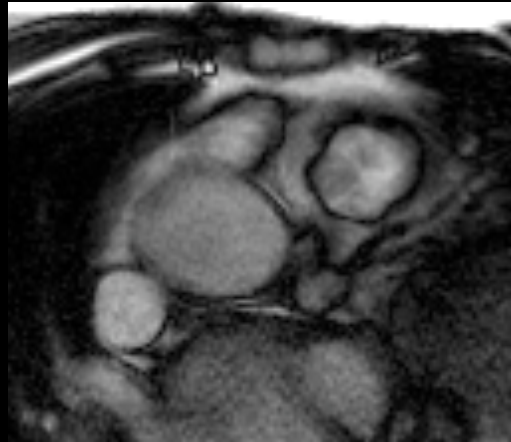
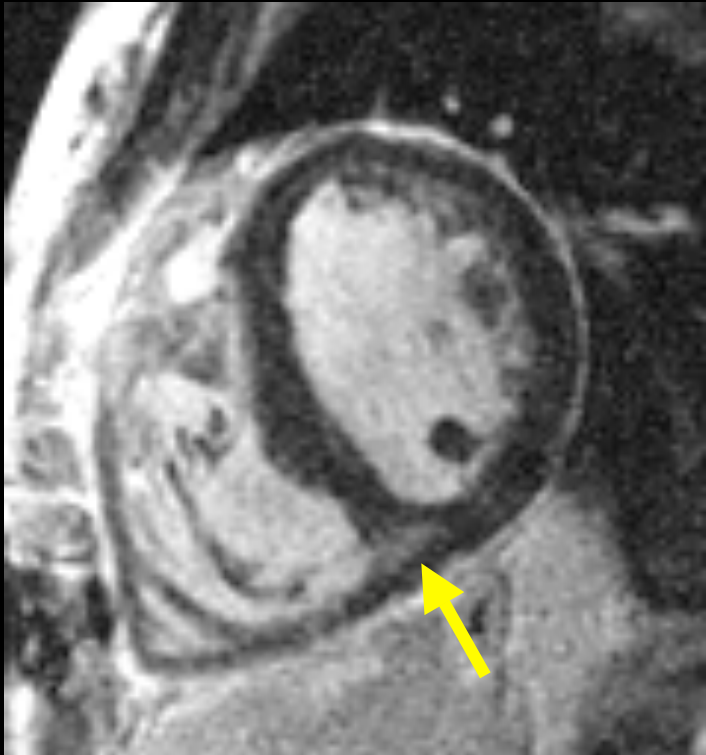Pulmonary valve stenosis

Non-CAD Pattern: RV insertion site



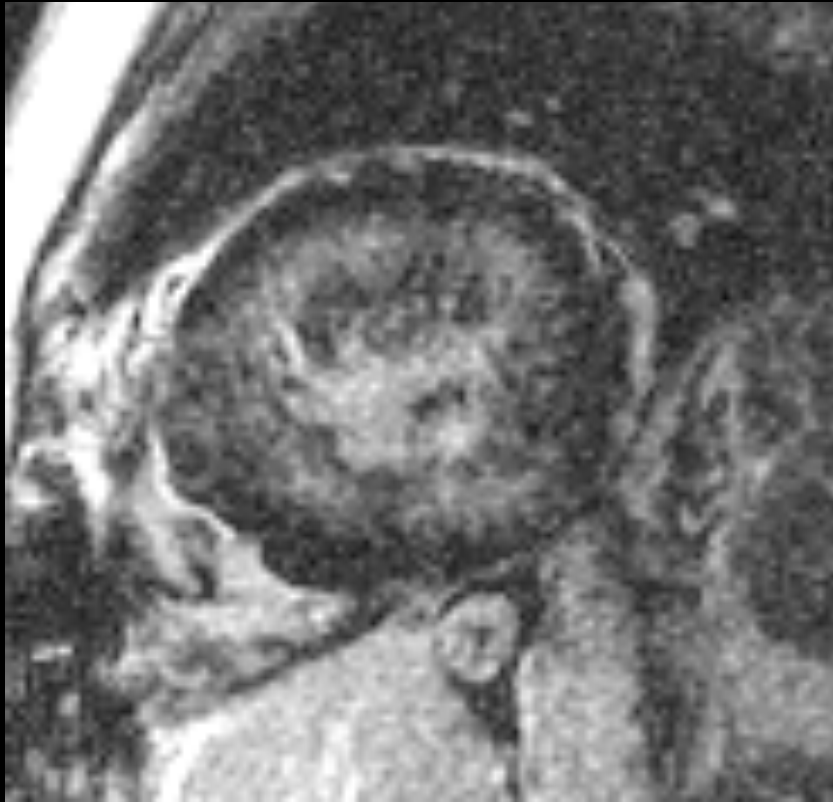
Pulmonary valve stenosis

Non-CAD Pattern: RV insertion site



Pulmonary valve stenosis

Non-CAD Pattern: diffuse subendocardial



AJR 2005; 184: 1420-1426

Int J Cardiovasc Imaging 2008;24:597-608


Non-CAD Pattern: diffuse subendocardial

Amyloidosis

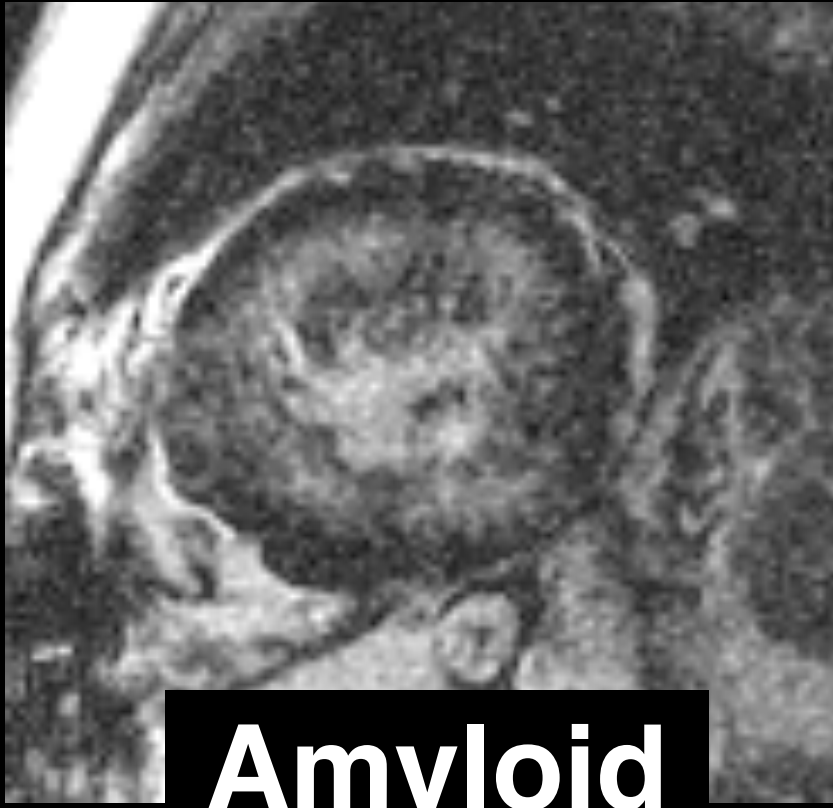System sclerosis

Cardiac trxplt


(Uremic CM)



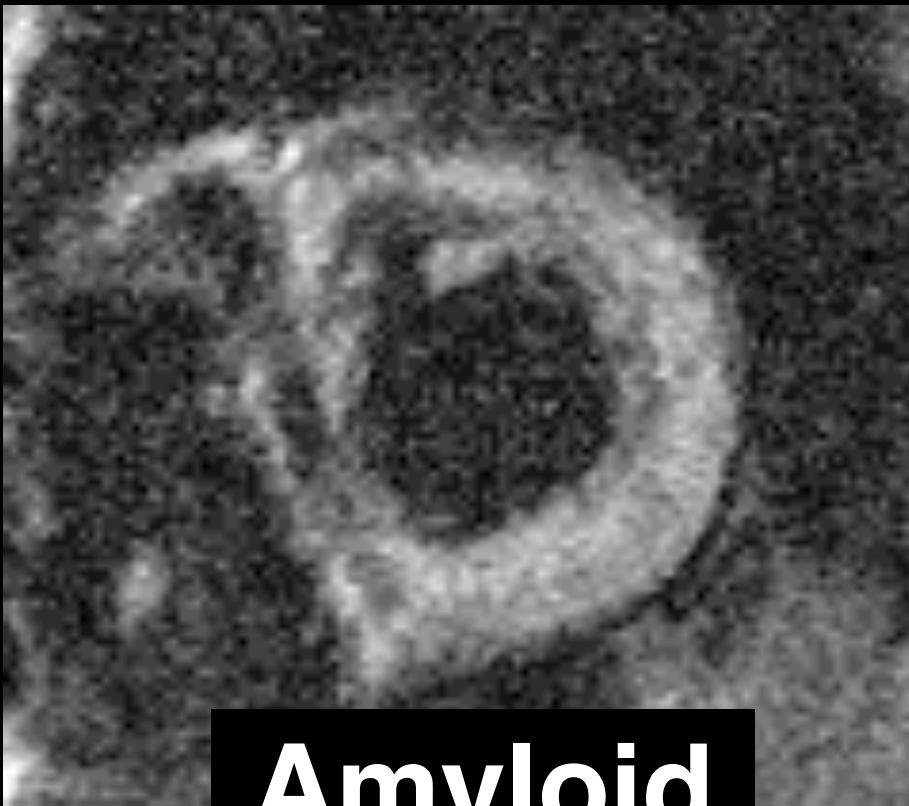
Non-CAD Pattern: diffuse subendocardial




Amyloid



Non-CAD Pattern: diffuse subendocardial



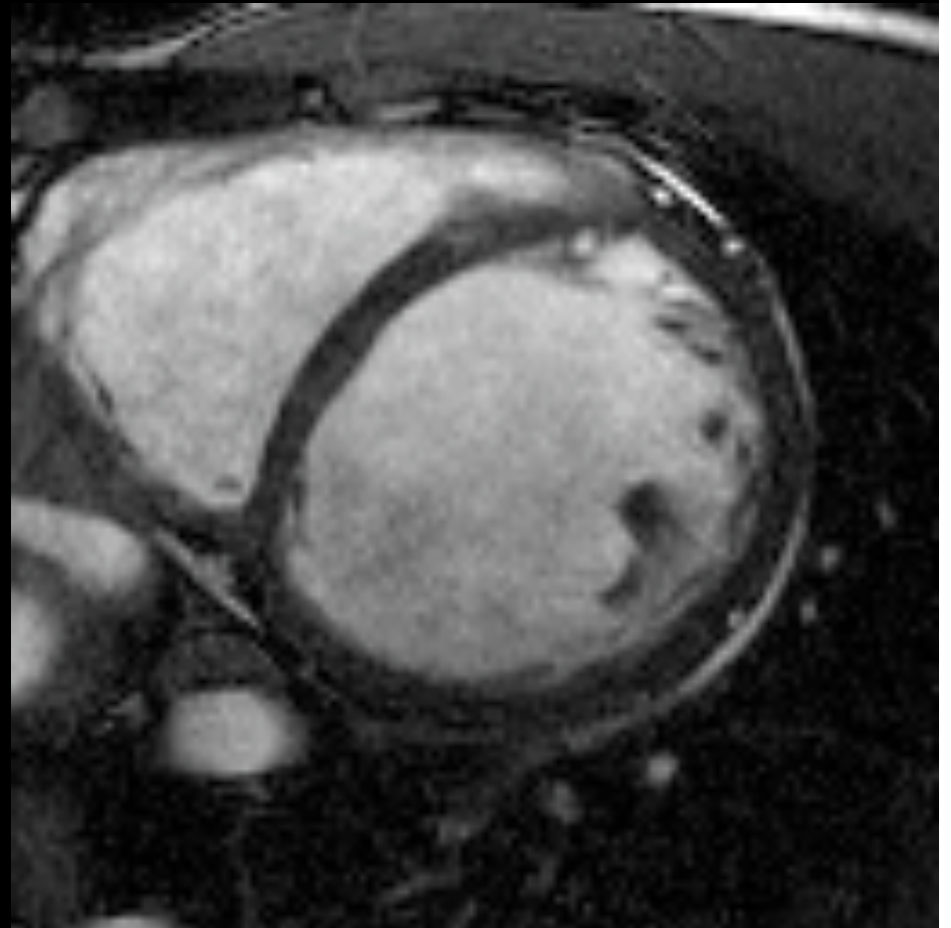
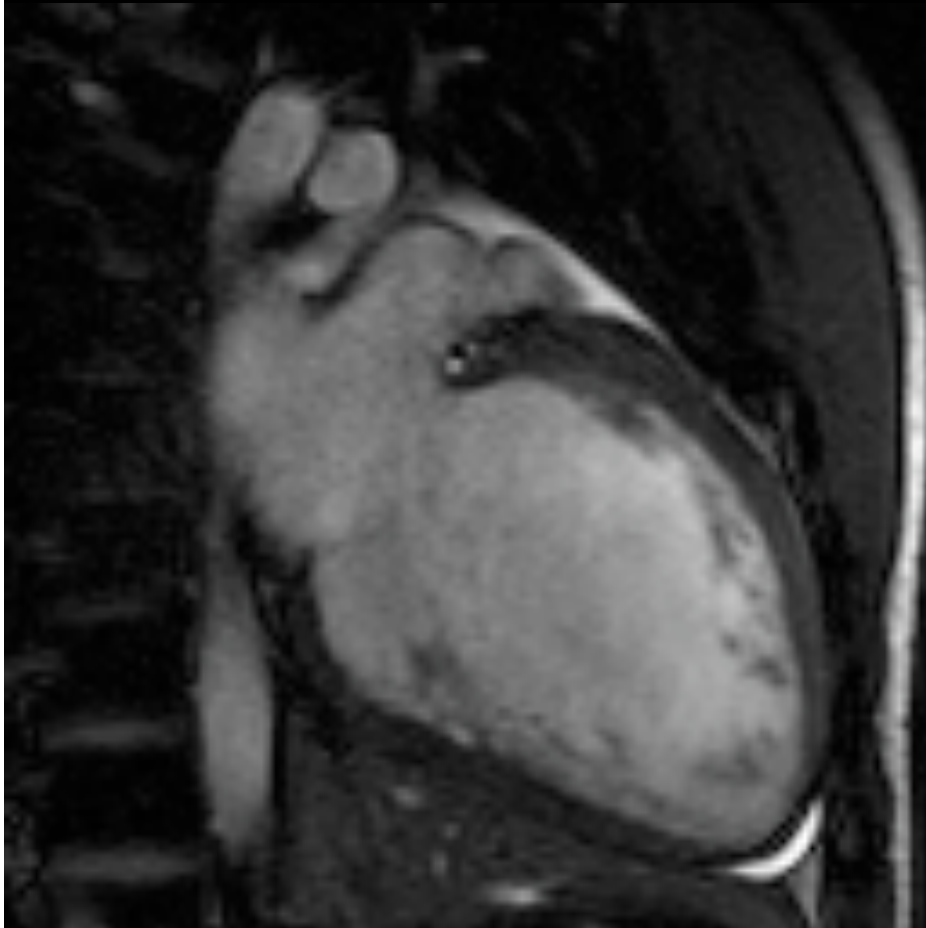
Amyloid



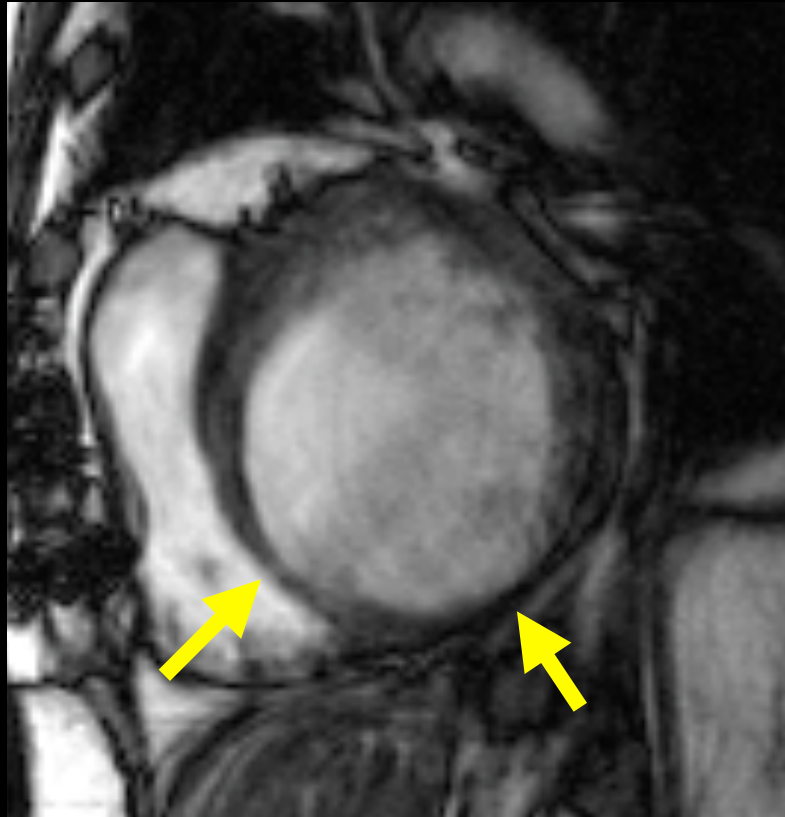
Myocardial Diseases

**Dilated
cardiomyopathy:
ischemic or not?**

**56 yo CHF; EtOH;
known CAD (LCx > 50%)**



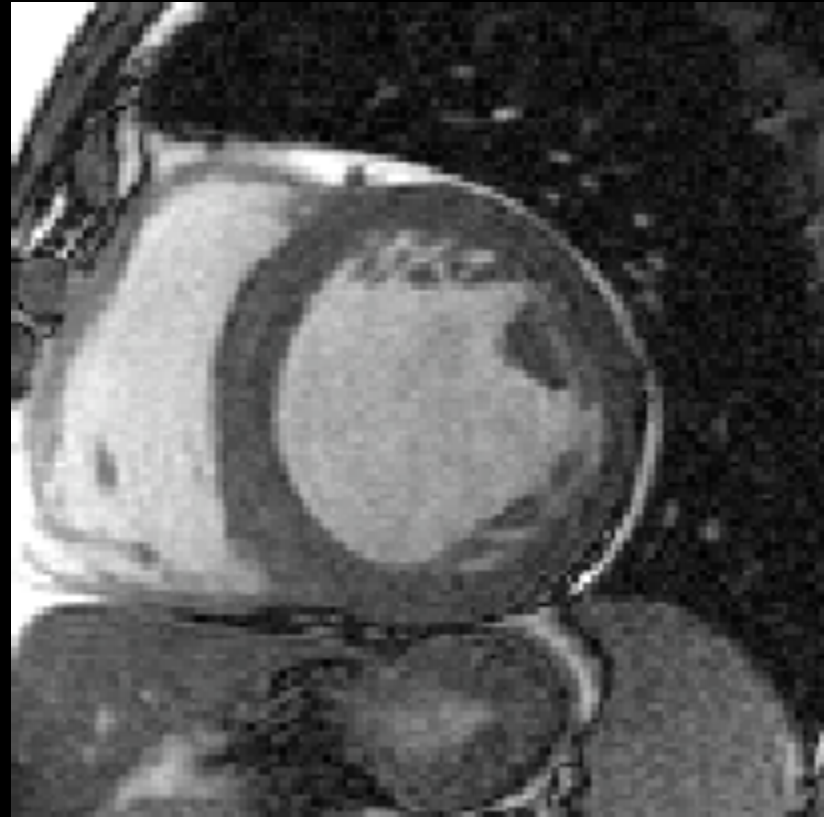
Ischemic



RV spared

Focal thinning

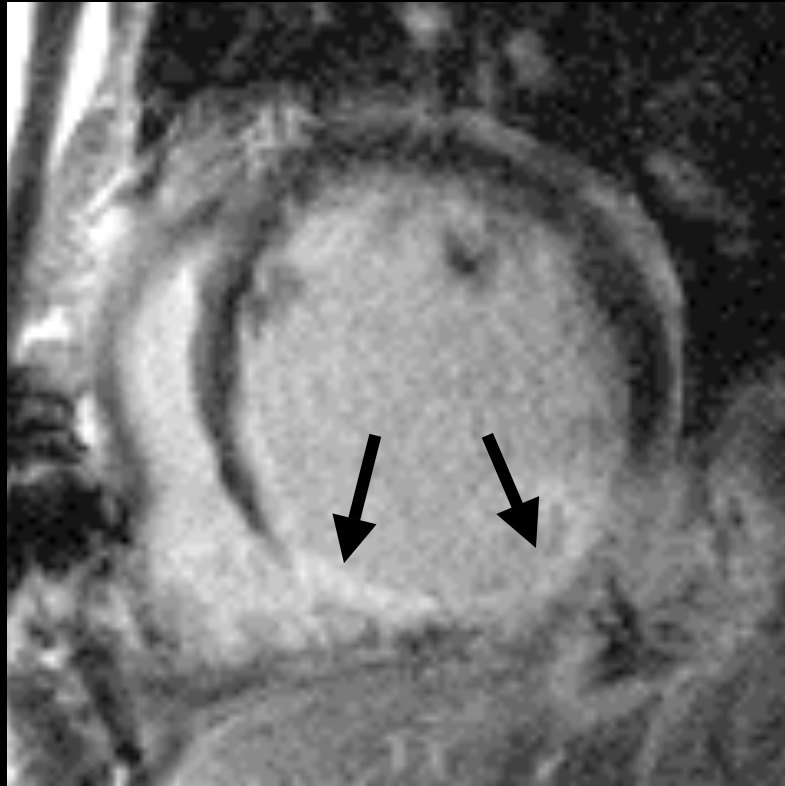Nonischemic



Biventricular

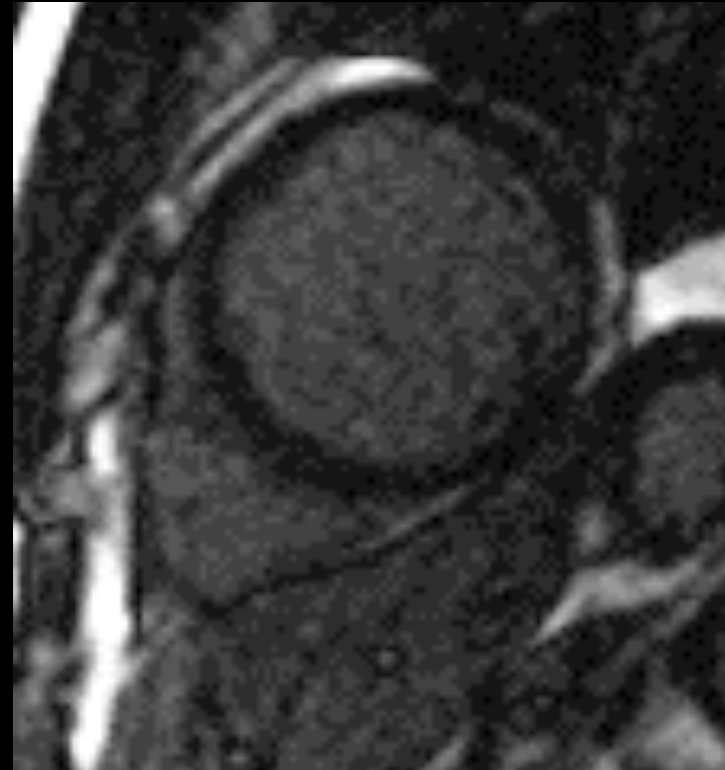
Uniform wall

Ischemic



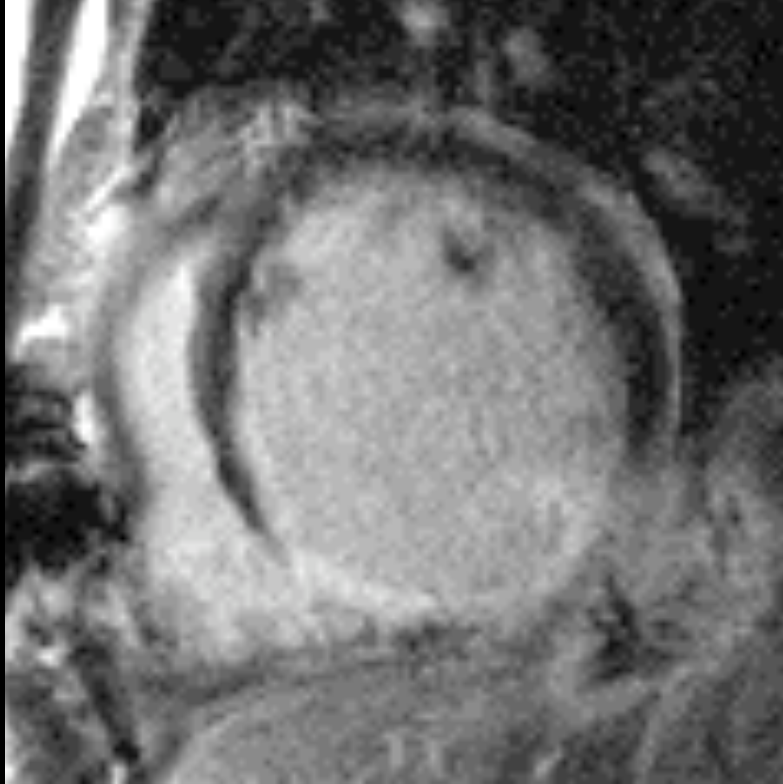
**Enhancement:
subendocardial,
transmural**

Nonischemic



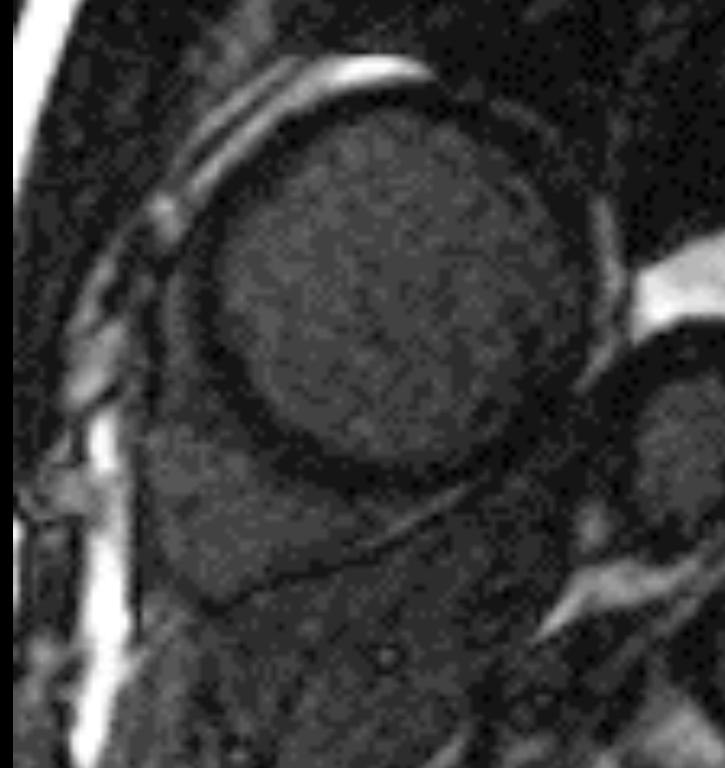
**Enhancement:
none**

Ischemic



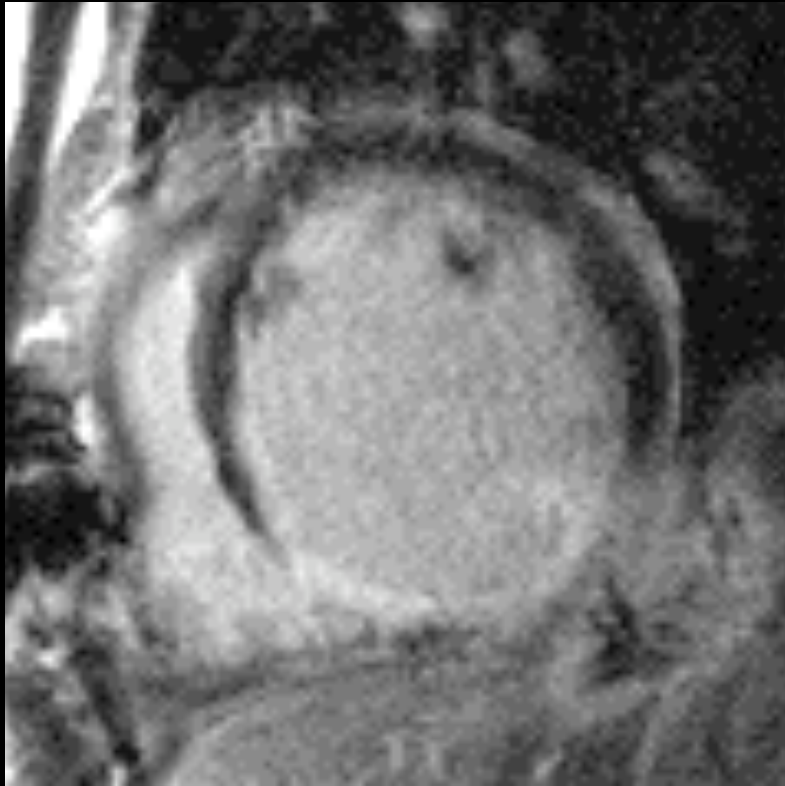
**Enhancement:
subendocardial,
transmural**

Nonischemic



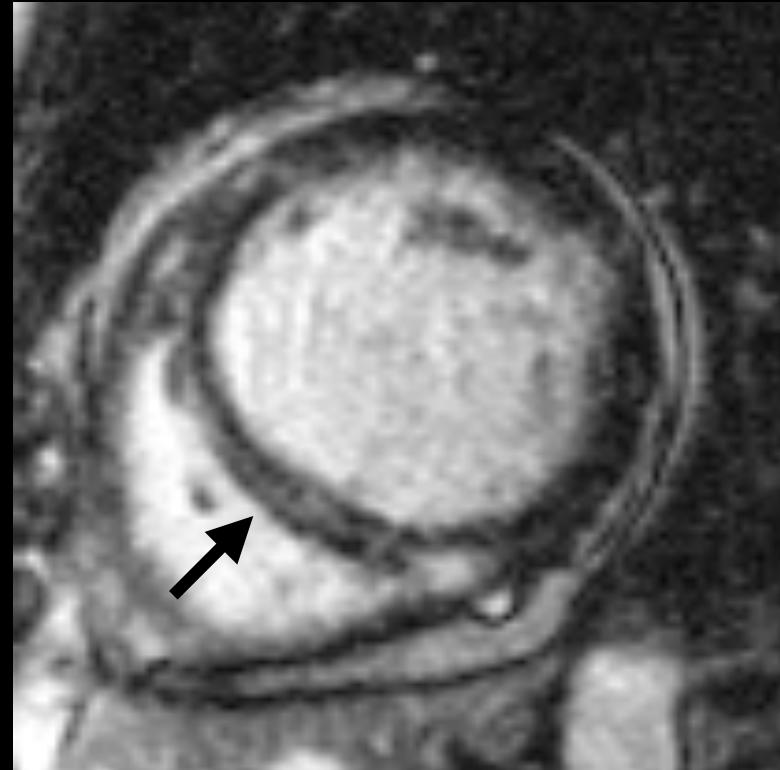**Enhancement:
none**

Ischemic



**Enhancement:
subendocardial,
transmural**

Nonischemic

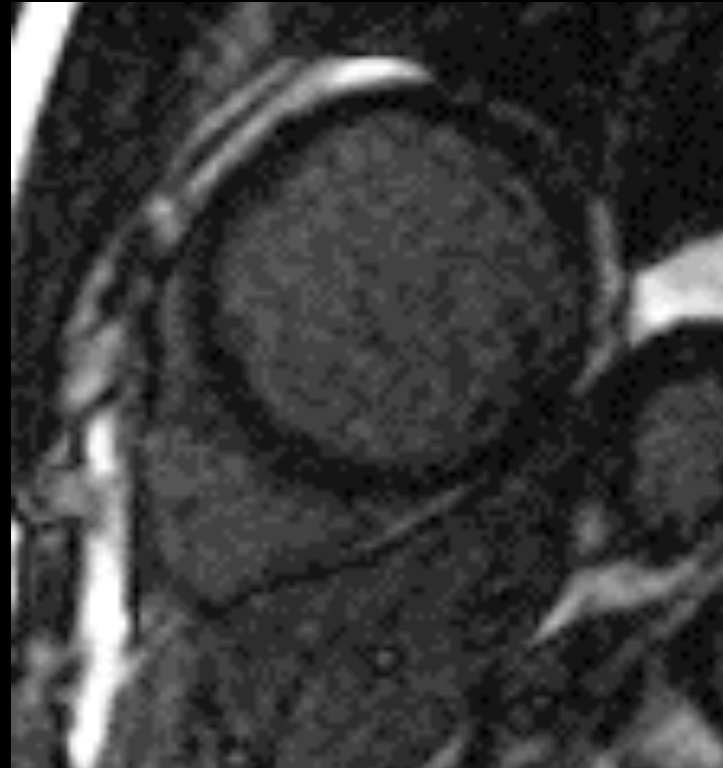
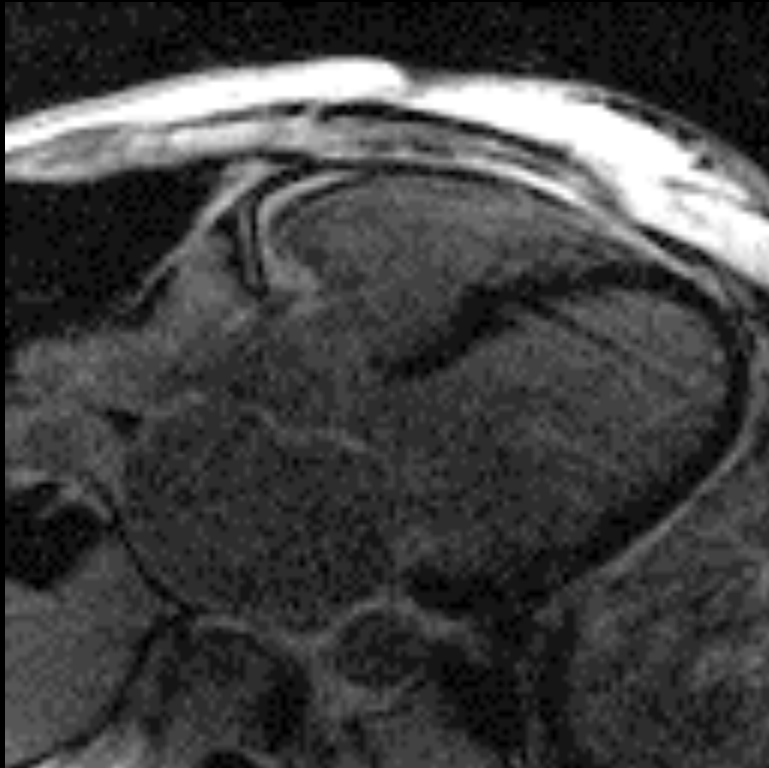


**Enhancement:
none,
nonischemic**

Nonischemic Cardiomyopathy

No Enhancement

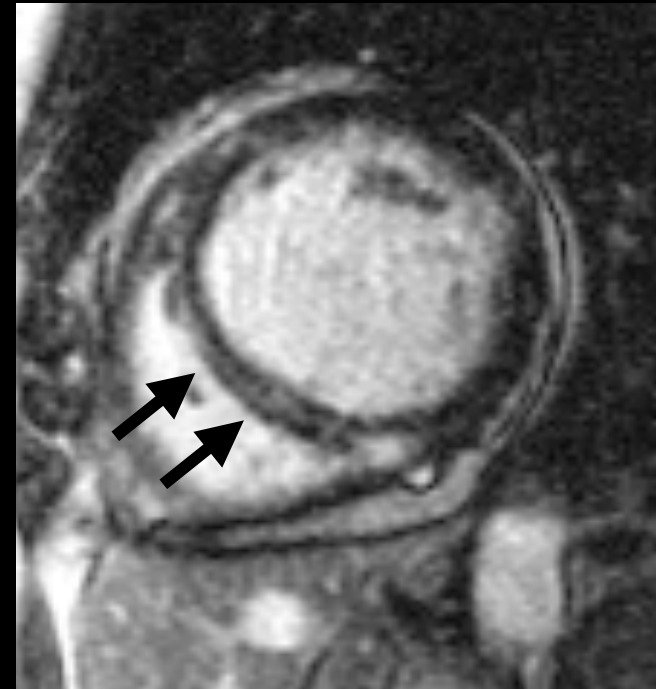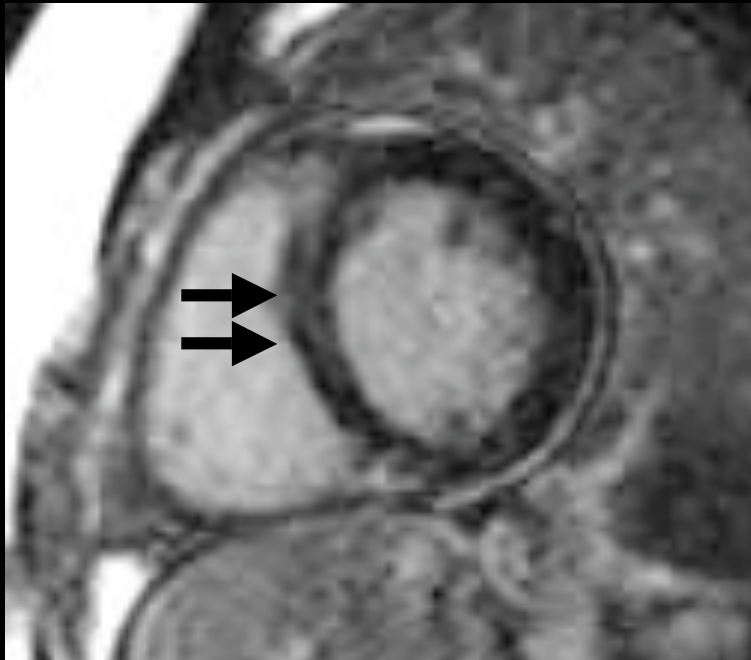
Alcoholic, Post-partum, Idiopathic



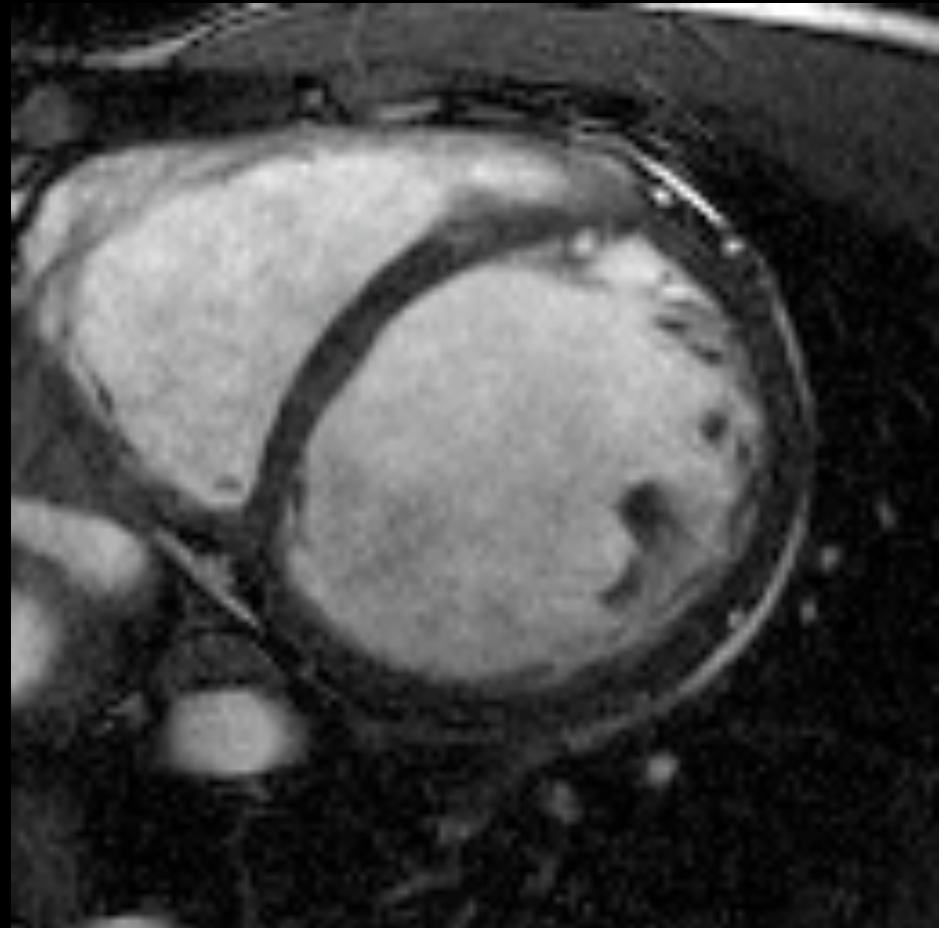
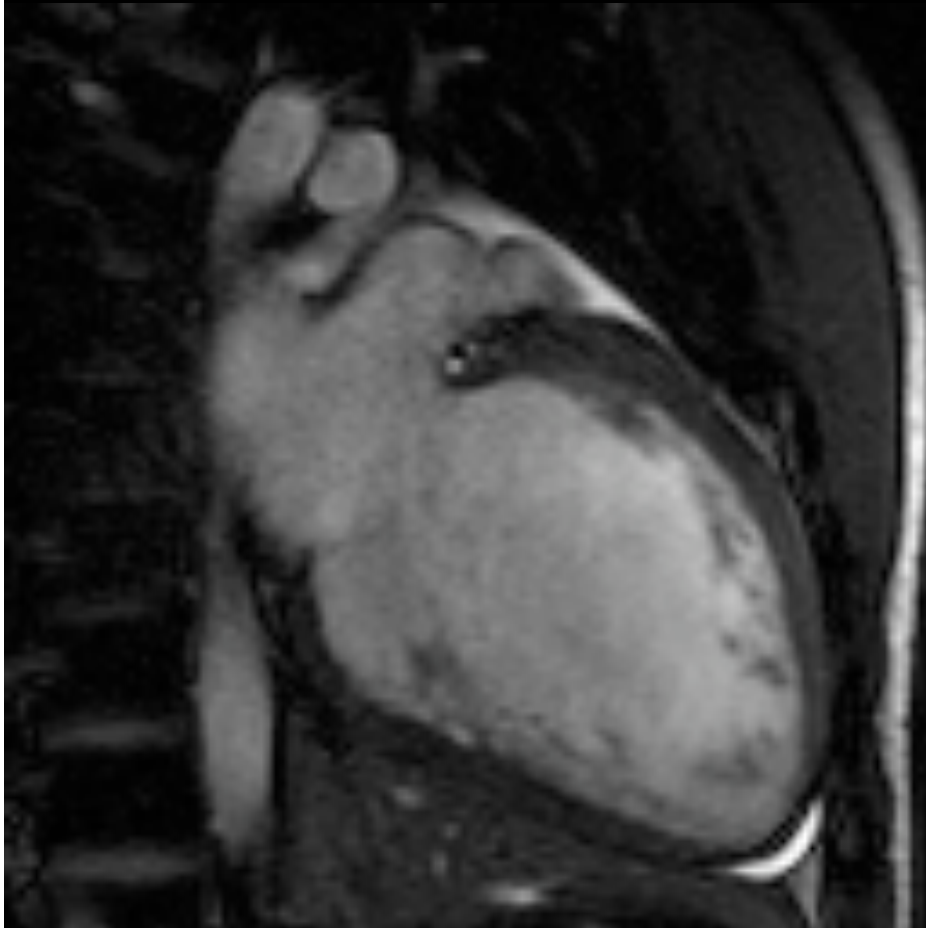
Nonischemic Cardiomyopathy

40% idiopathic CM

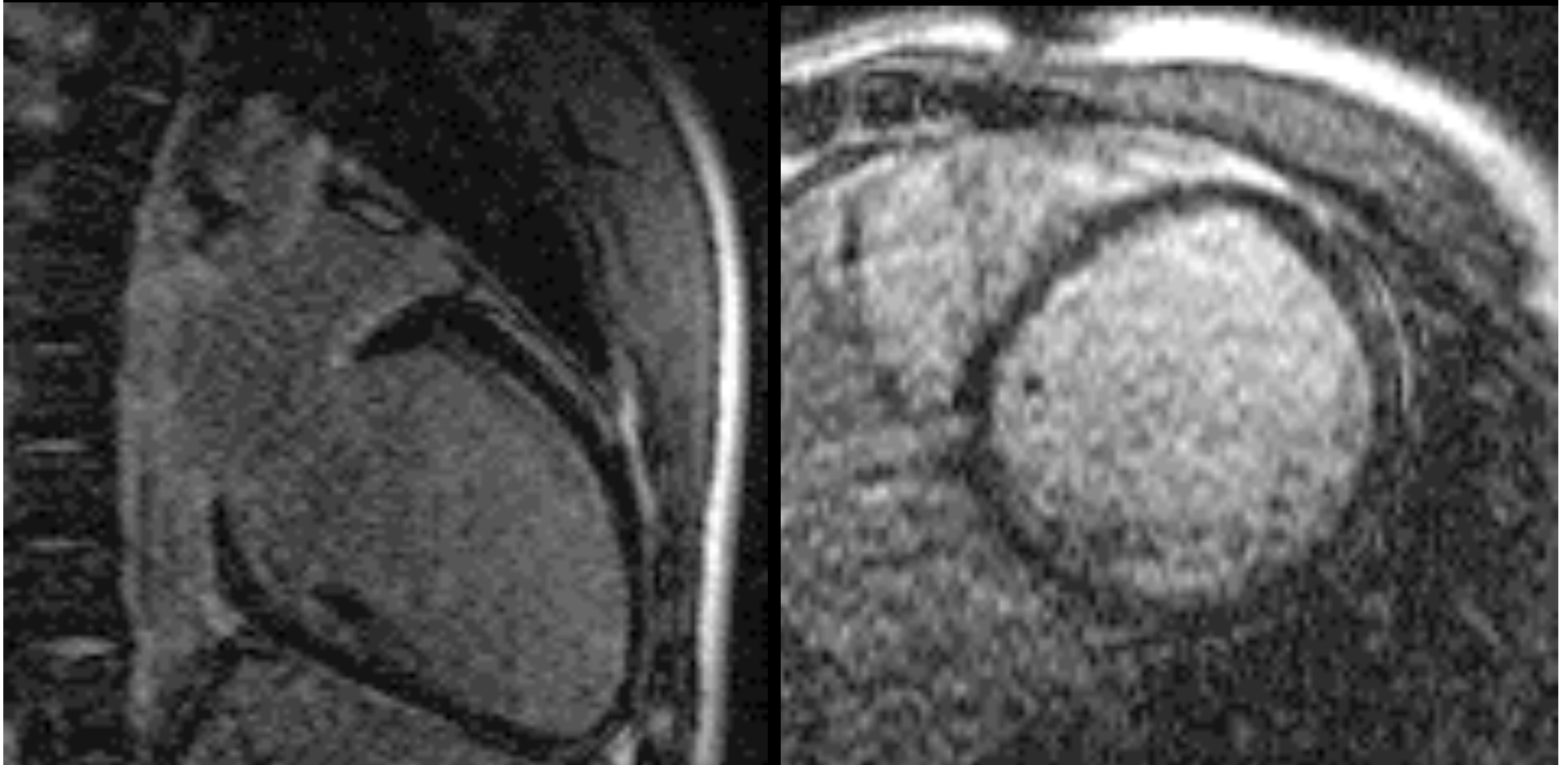
nonischemic pattern: midwall



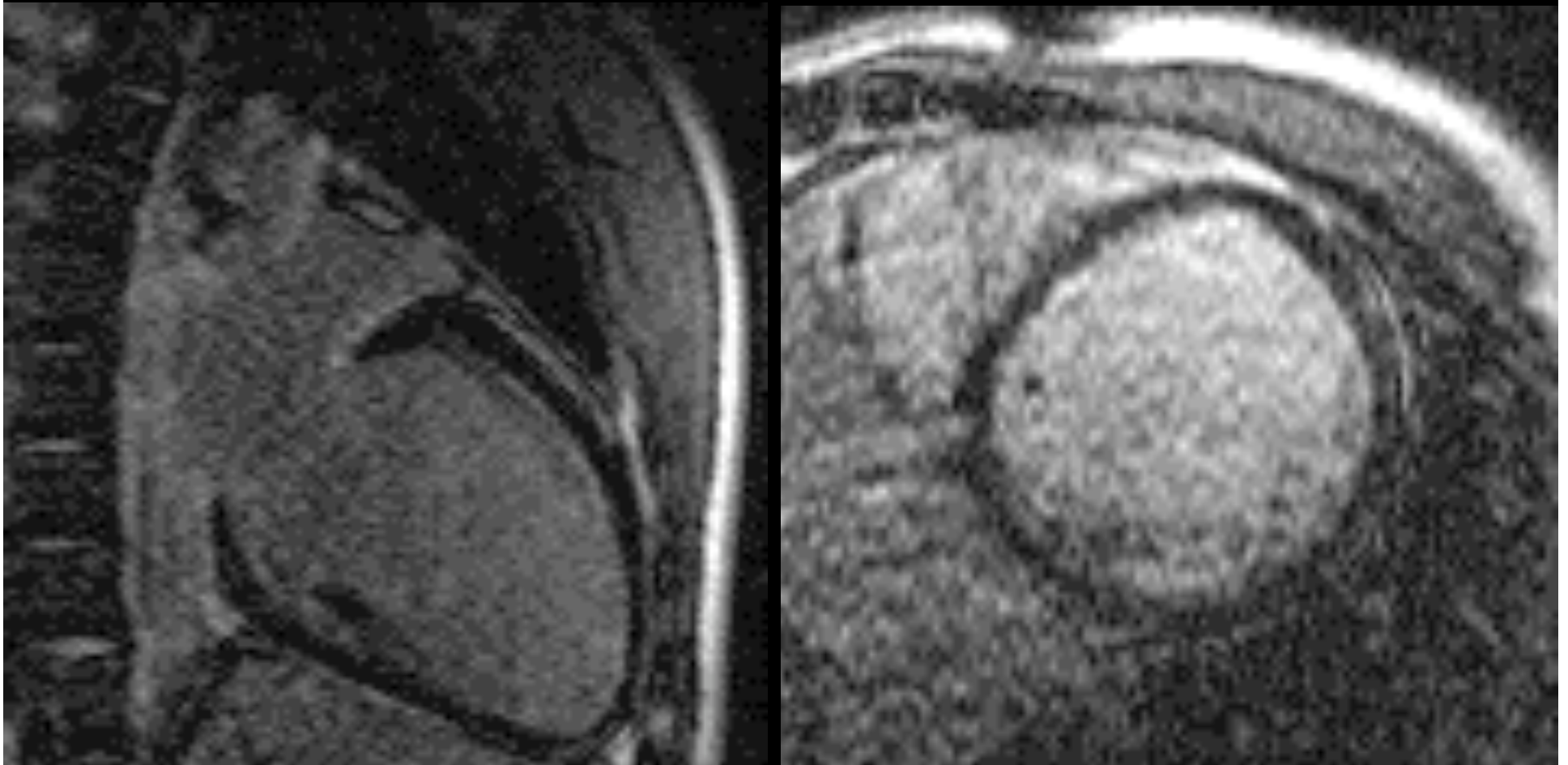
**56 yo CHF; EtOH;
known CAD (LCx > 50%)**



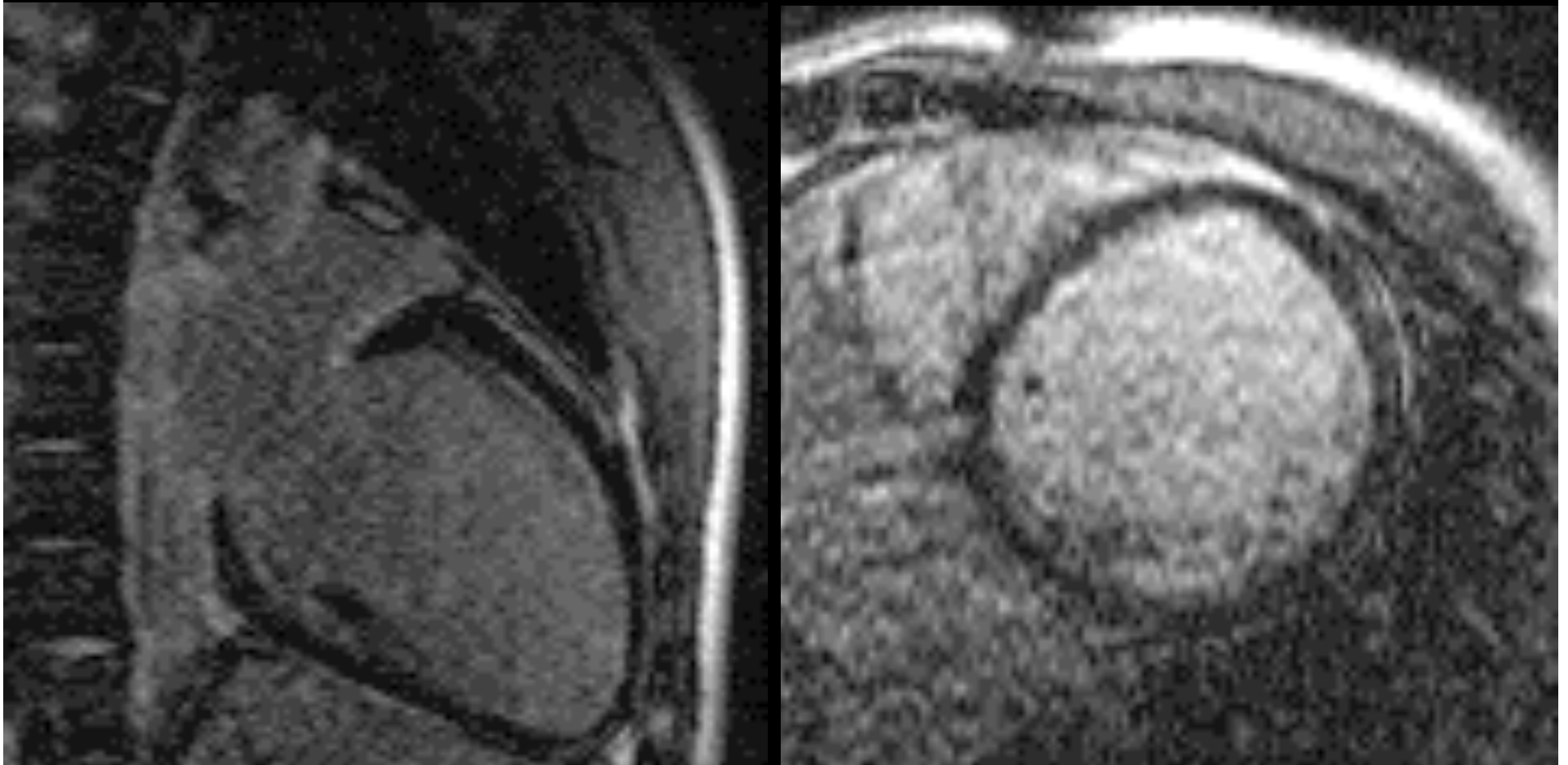
**56 yo CHF; EtOH;
known CAD (LCx > 50%)**



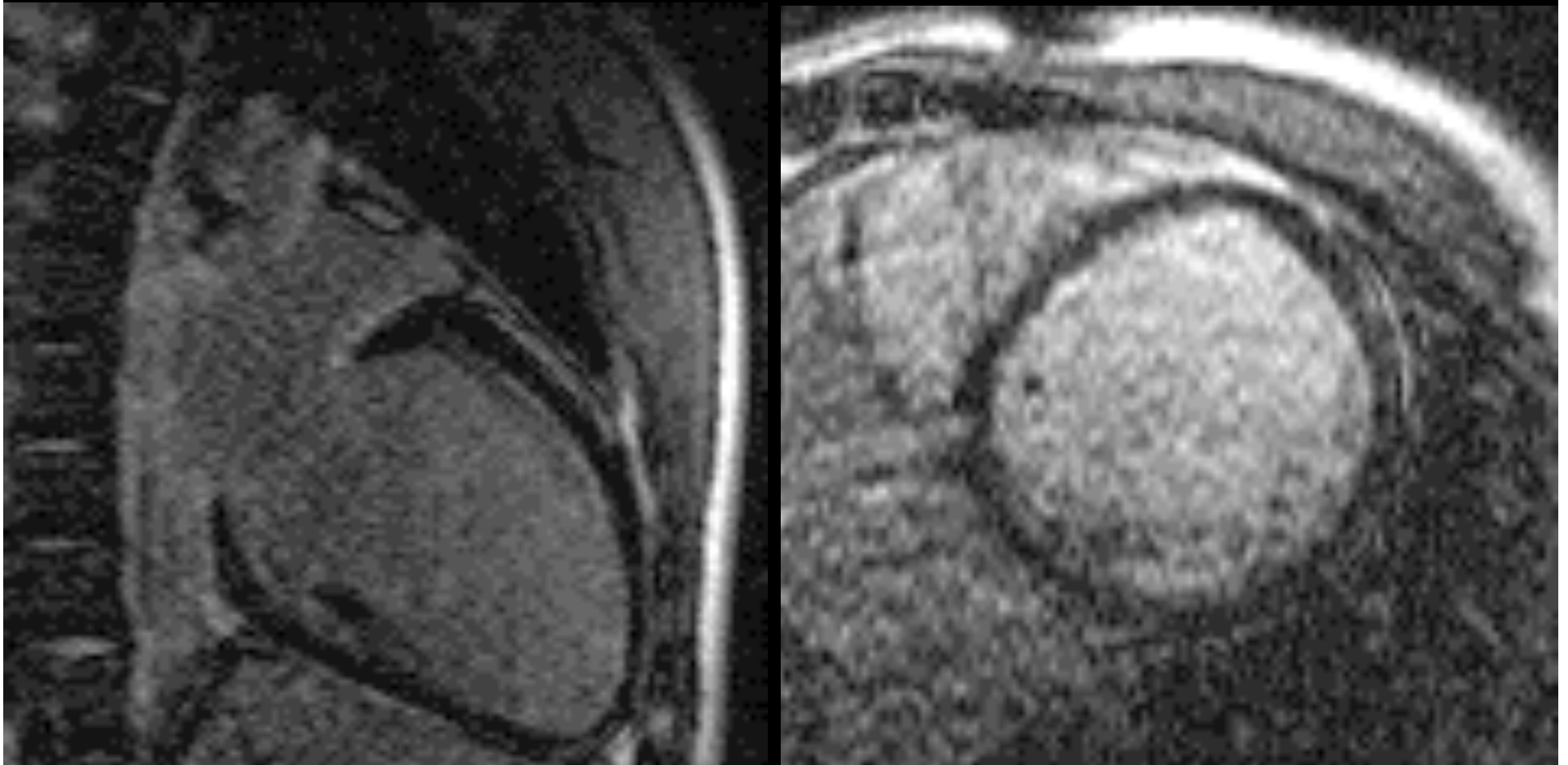
Nonischemic Cardiomyopathy



Alcoholic Cardiomyopathy



**Revascularization?
probably not improve**



**Sudden cardiac
death
in young patient:
? cause**

Sudden Cardiac Death in Young Patient

- **Cardiac sarcoid**
- **Hypertrophic CM**
- **Arrhythmogenic RV dysplasia**
- **Anomalous coronary**

Sudden Cardiac Death in Young Patient

- **Cardiac sarcoid**
- **Hypertrophic CM**
- **Arrhythmogenic RV dysplasia**
- **Anomalous coronary**

Sudden Cardiac Death in Young Patient

- **Cardiac sarcoid**
- **Hypertrophic CM**
- **Arrhythmogenic RV dysplasia**
- **Anomalous coronary**

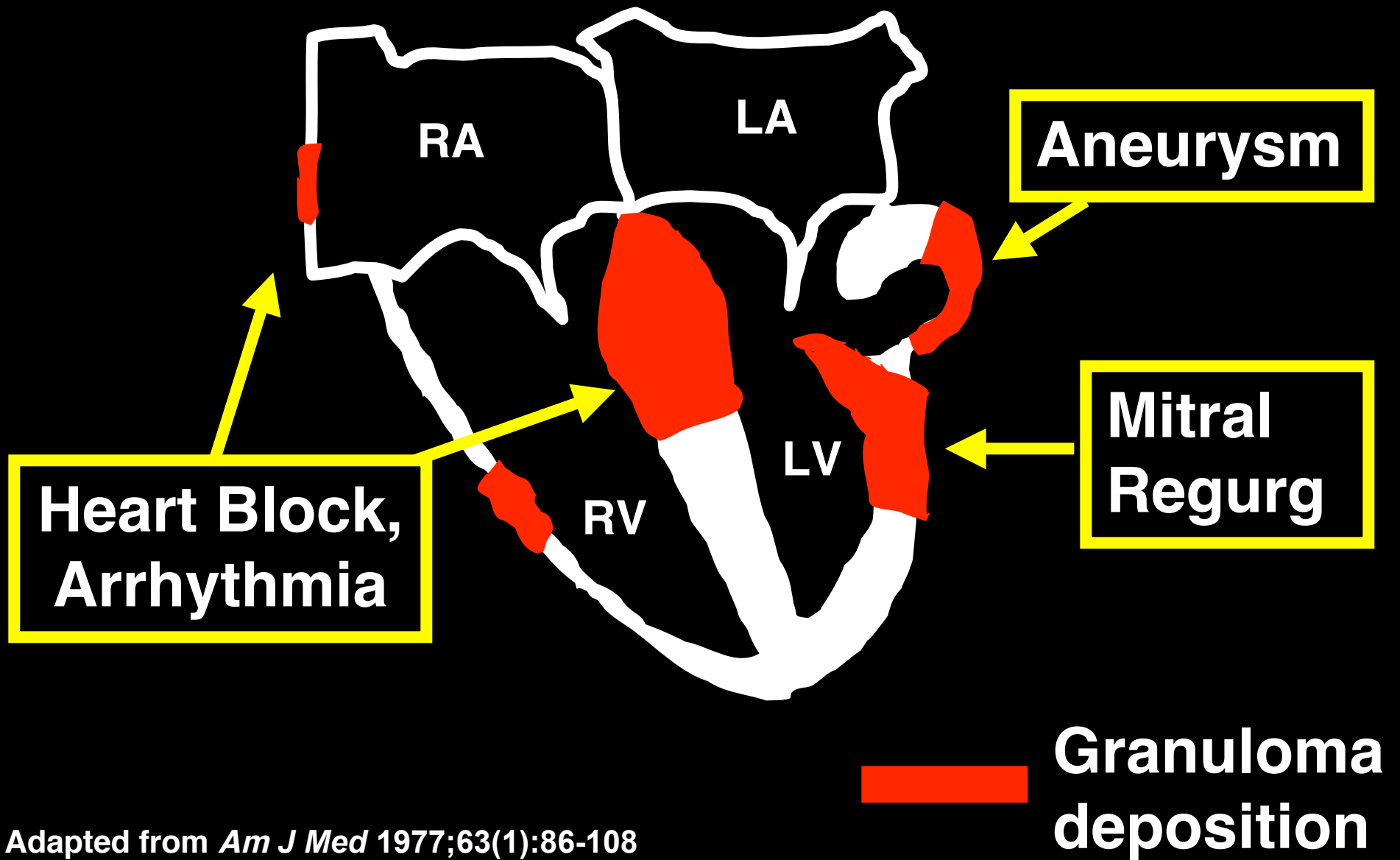
Sudden Cardiac Death in Young Patient

- **Cardiac sarcoid**
- Hypertrophic CM
- Arrhythmogenic RV dysplasia
- Anomalous coronary

Cardiac Sarcoidosis

- **Multi-organ system**
- **5% clinical cardiac dz**
- **Risk of arrhythmia, SCD**
- **Treatment: defibrillator**

Sarcoidosis



Adapted from *Am J Med* 1977;63(1):86-108

Japanese Ministry of Health

Criteria A + at least 1 from B-D

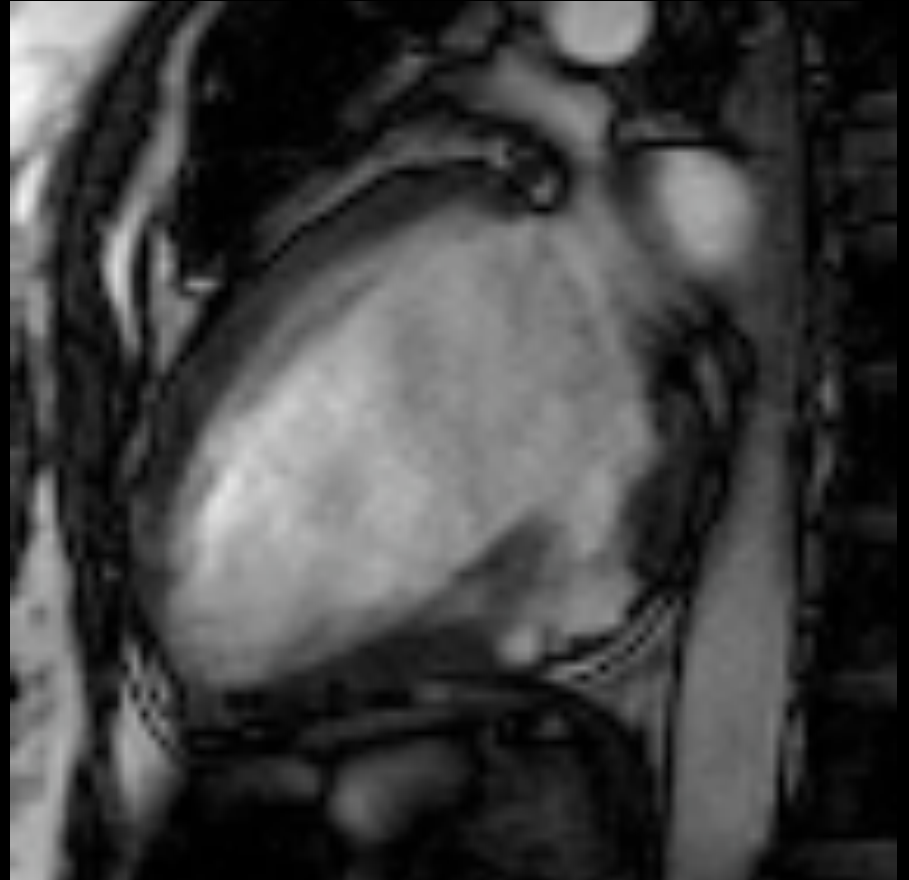
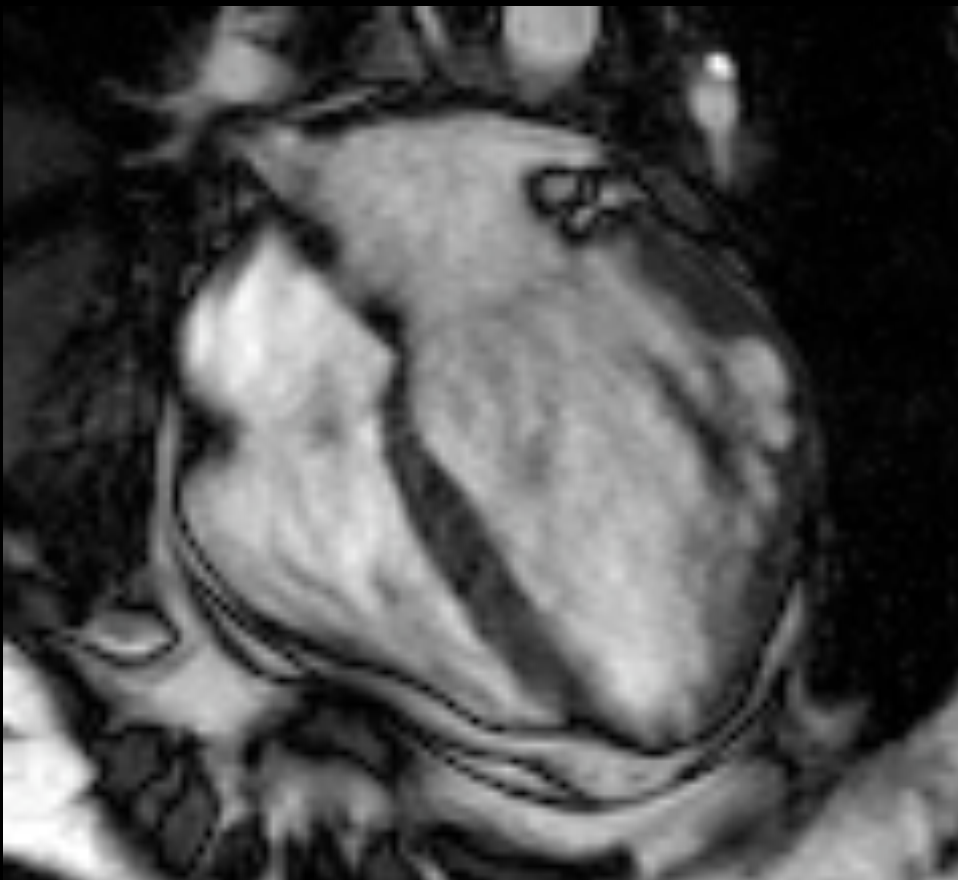
Criteria A: Abnormal EKG or holter

Criteria B: Abnormal ECHO

Criteria C: Abnormal nuclear study
(perfusion defect or abnormal 67-Ga citrate scan)

Criteria D: Abnormal cath
(abnormal wall motion or EF)

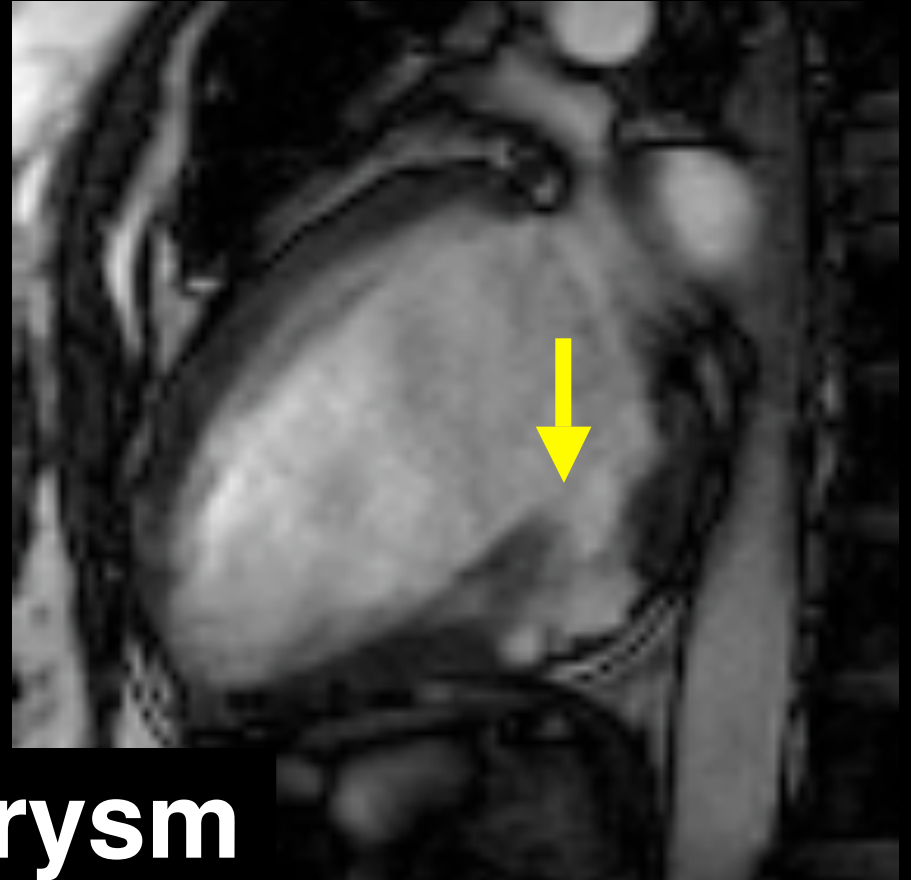
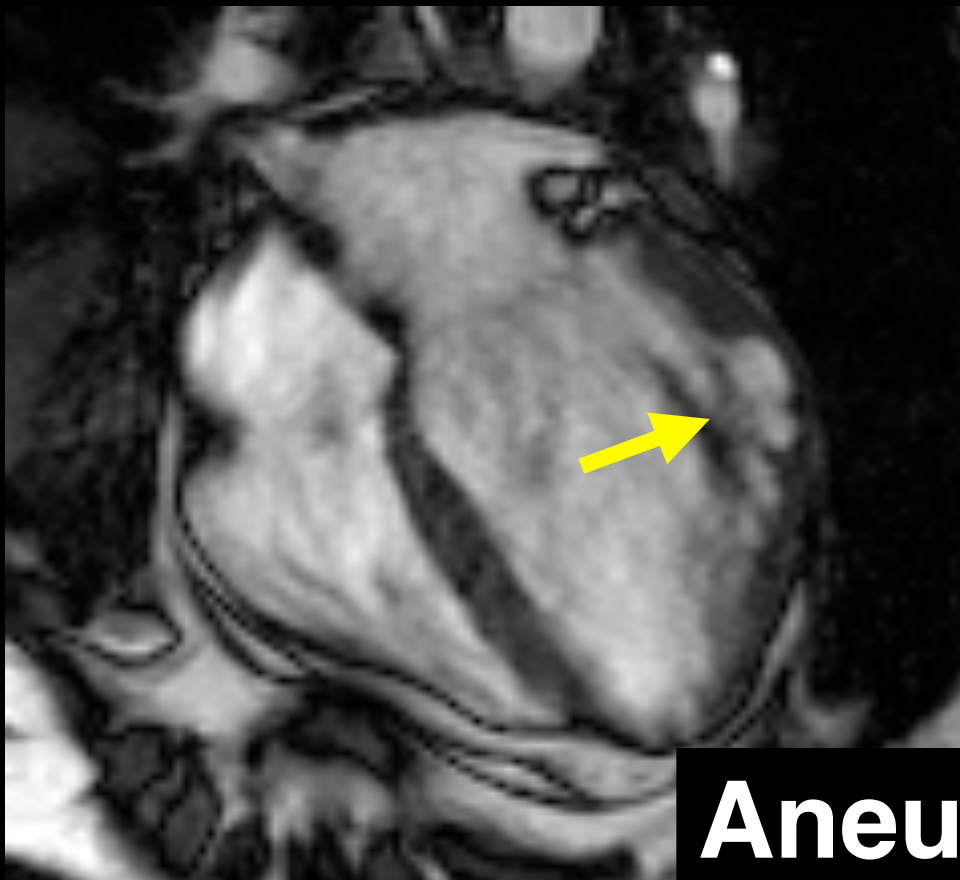
MRI spatial resolution surpasses ECHO, nucs



Cardiol Clin 2007; 25: 71-95.

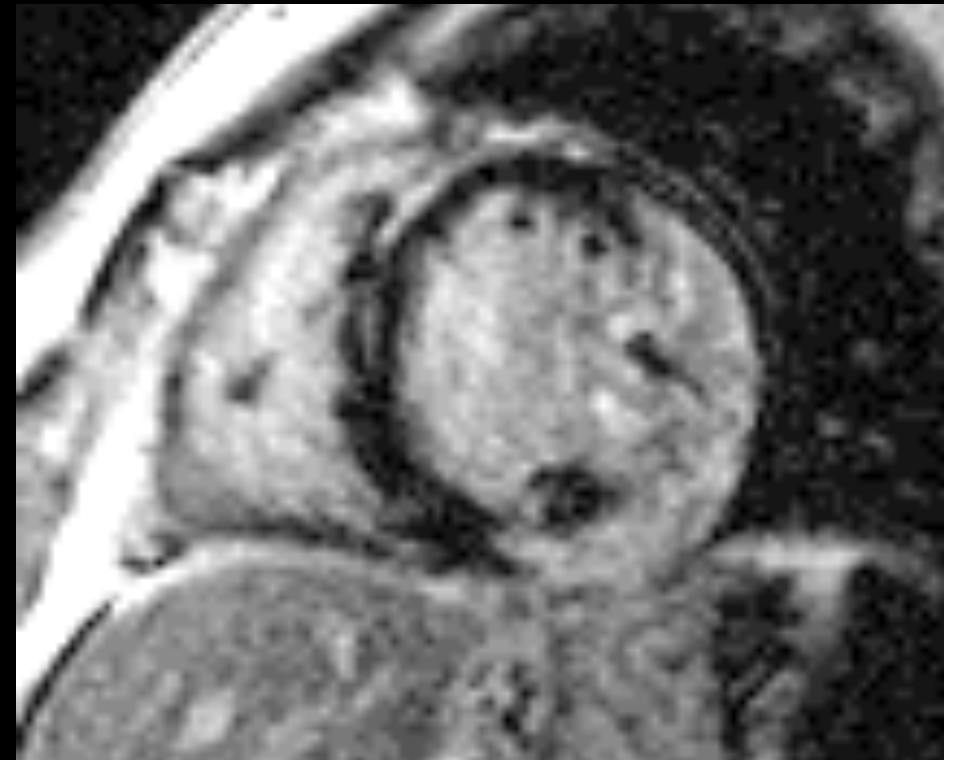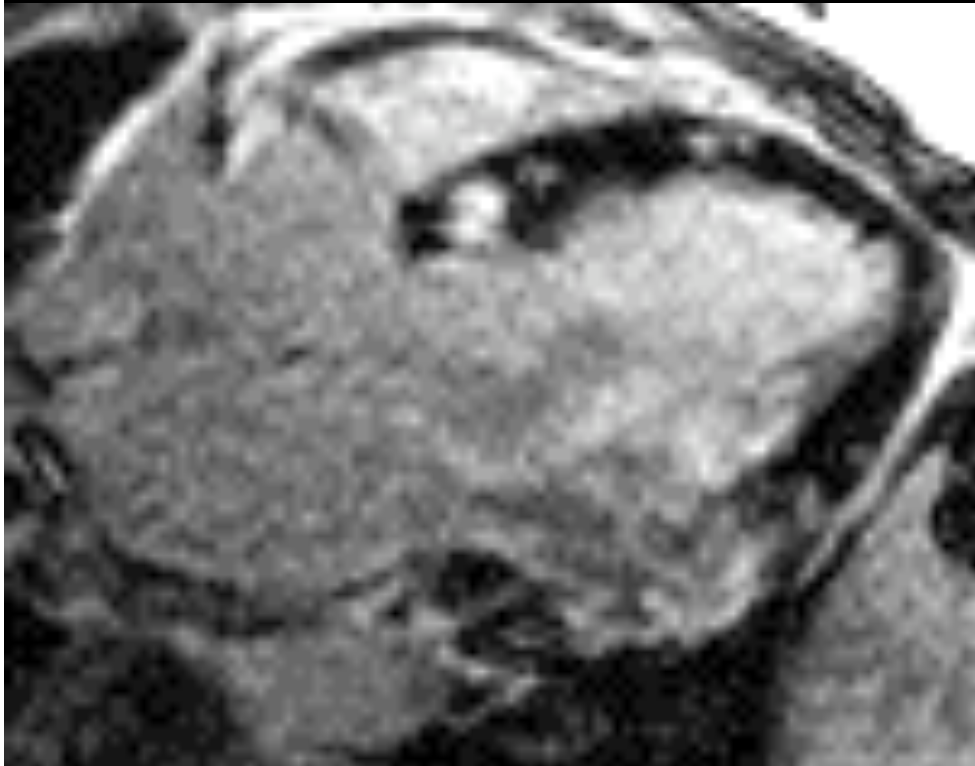AJR 2005; 184: 1420-1426

45 yo, lung sarcoid, normal cath, +/- ECHO



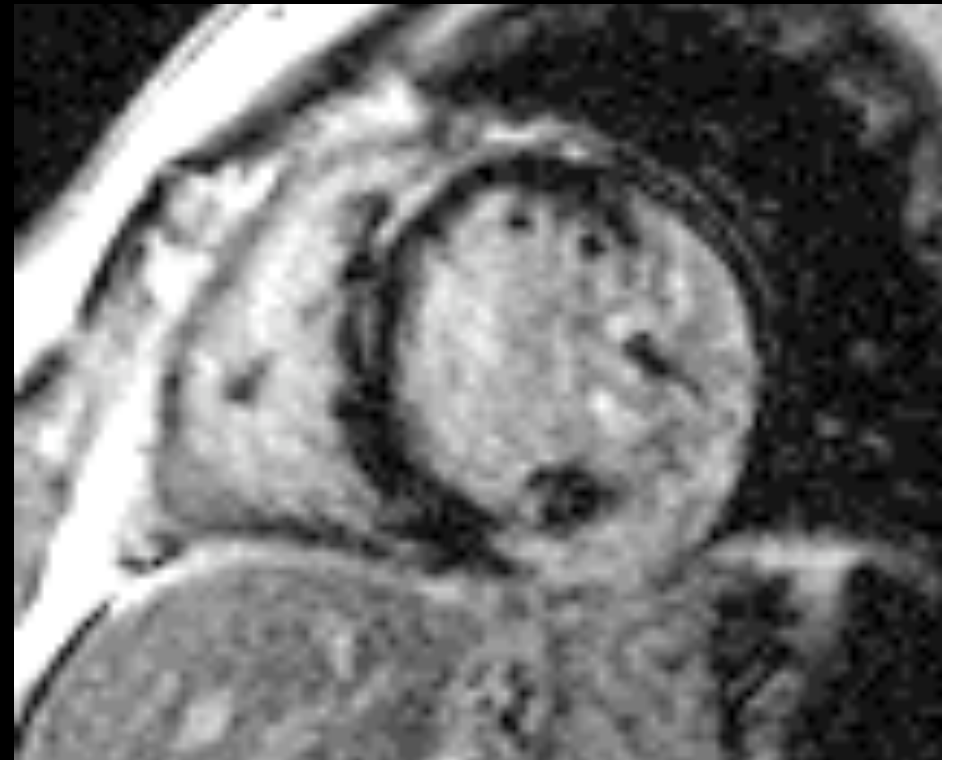Aneurysm

Delayed Enhancement often nonischemic pattern



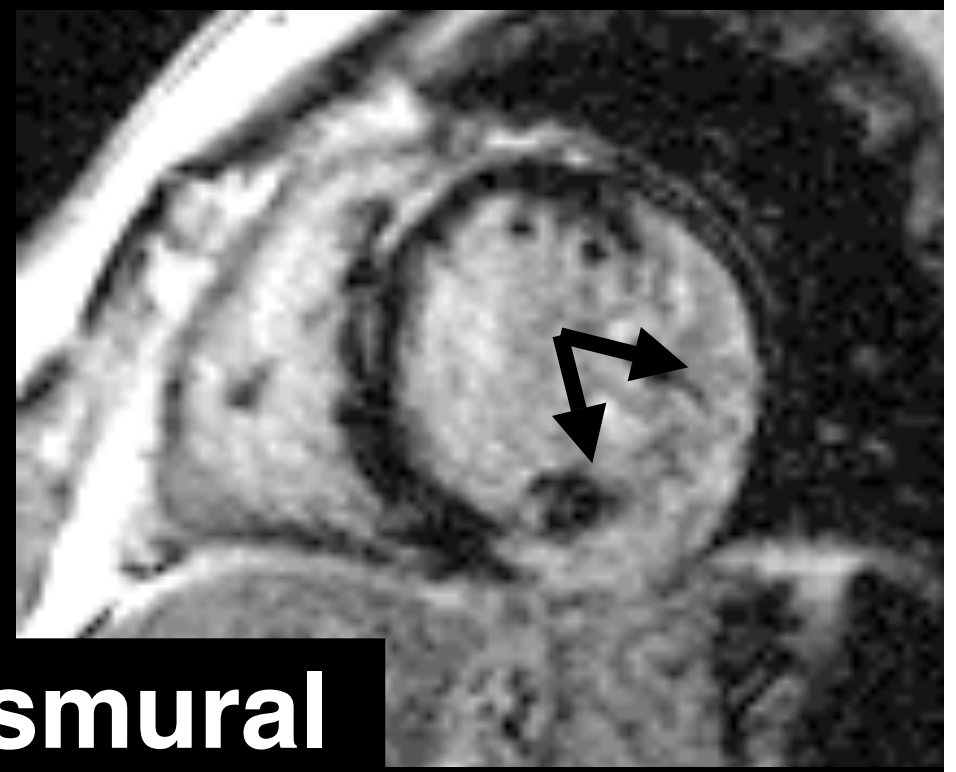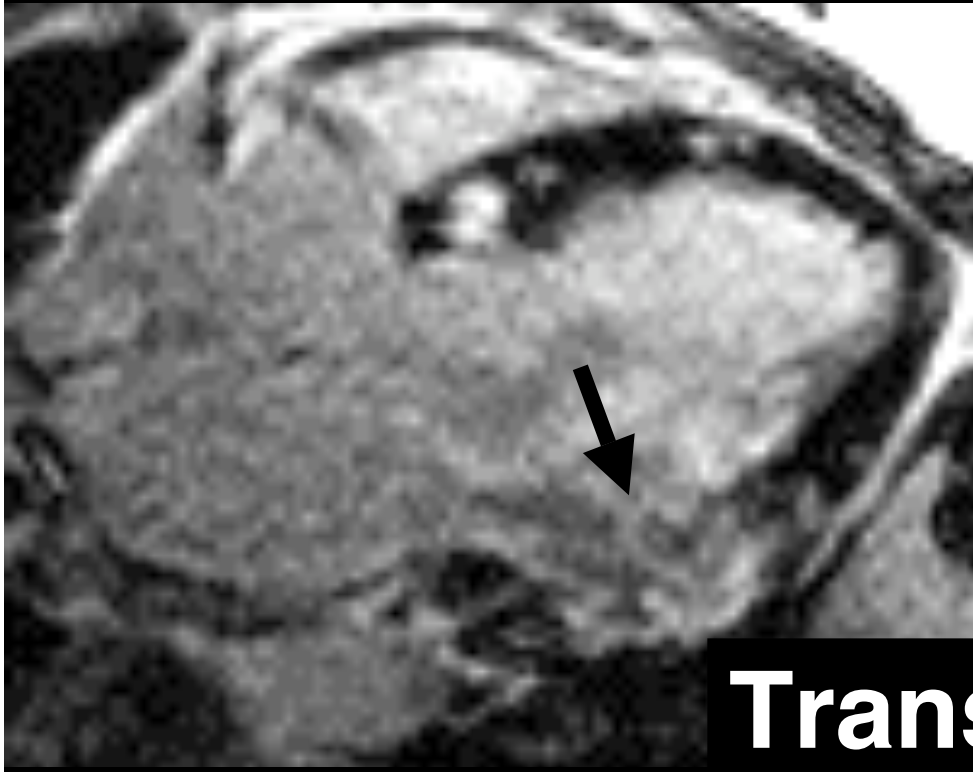
Circulation 2004;108:645 (suppl)

**Patel: 70 pts sarcoid
24% + enhancement
(2x Japanese criteria)**



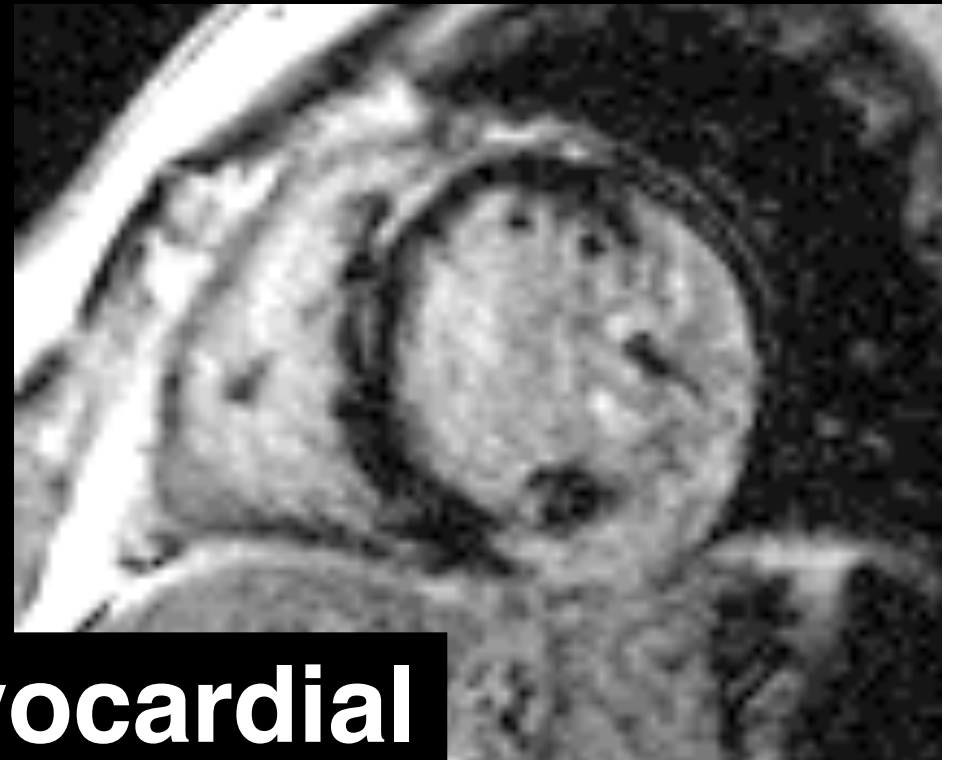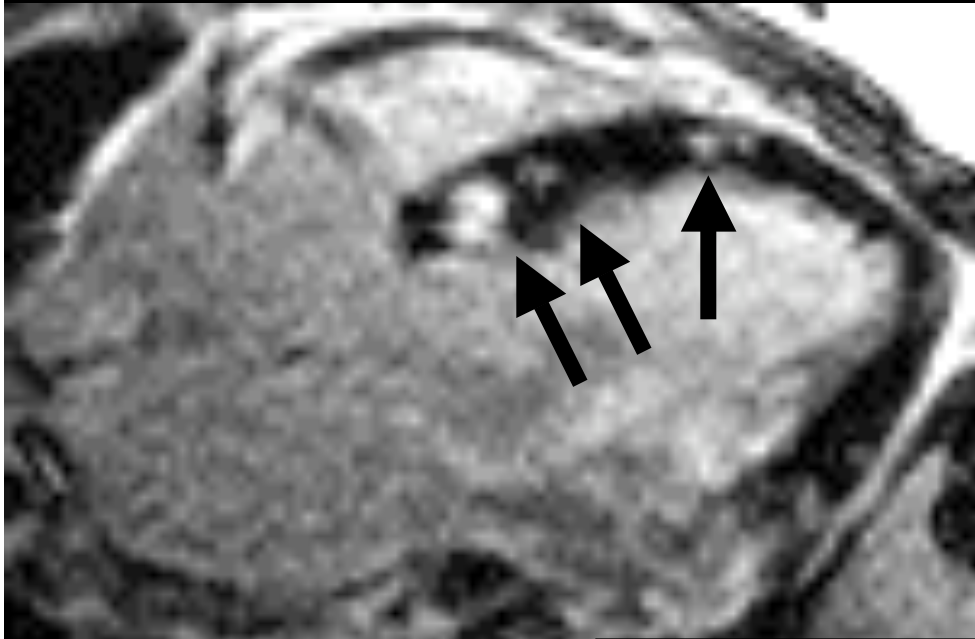
Circulation 2006; 114 (suppl II): 408

Patel: 70 pts sarcoid enhancement patterns transmural: nl coronaries



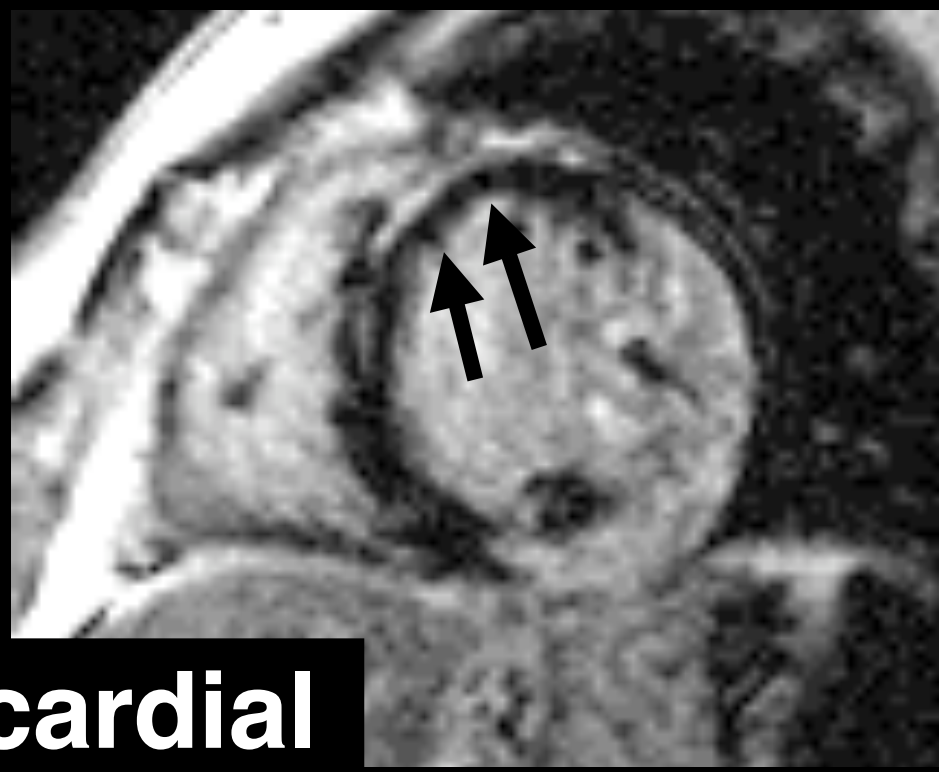
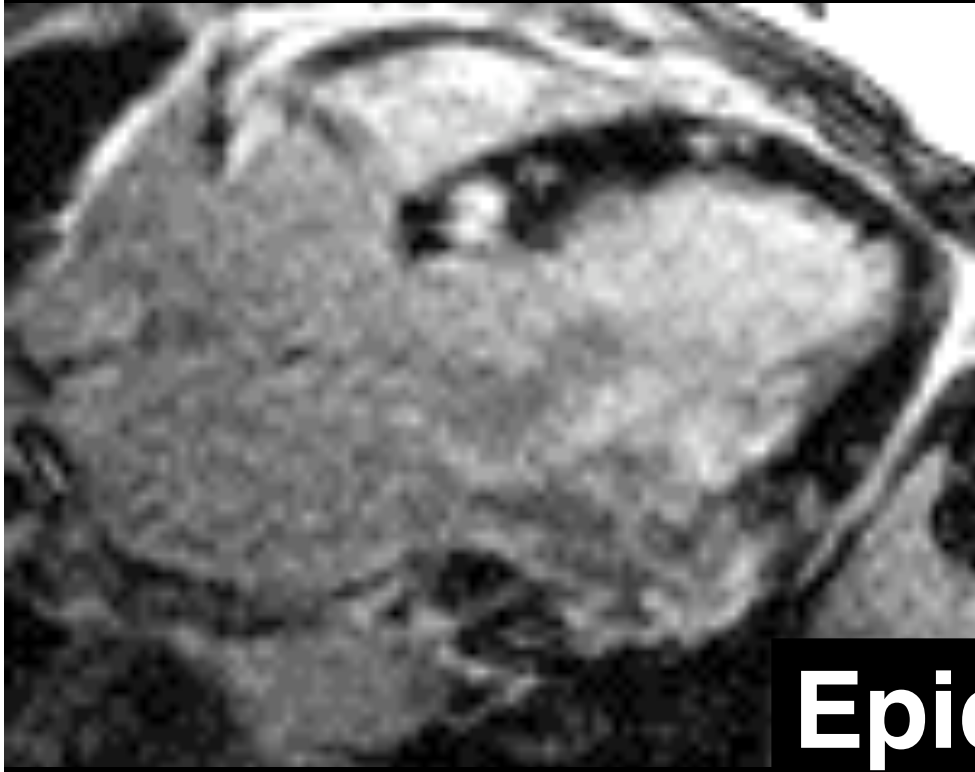
Transmural

**Patel: 70 pts sarcoid
enhancement patterns
82% focus nonischemic**



Mid-myocardial

**Patel: 70 pts sarcoid
enhancement patterns
82% focus nonischemic**



Epicardial

Patel: 70 pts sarcoid
DE: independent predictor
of cardiac events



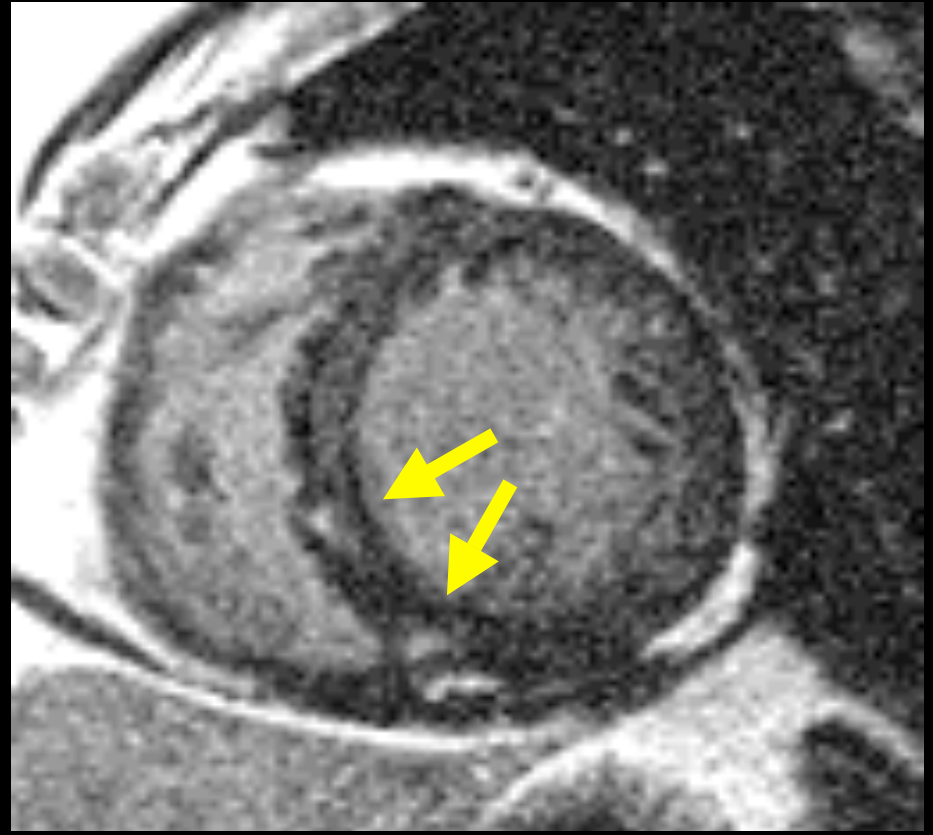
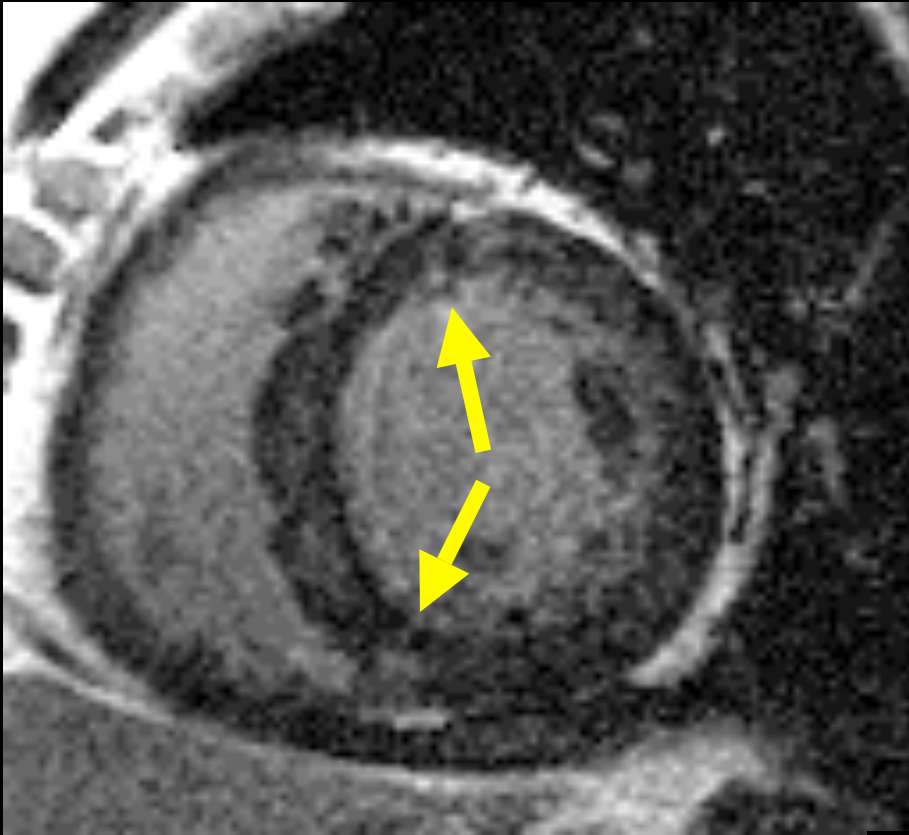
Circulation 2006; 114 (suppl II): 408



Cardiol Clin 2007; 25: 71-95.

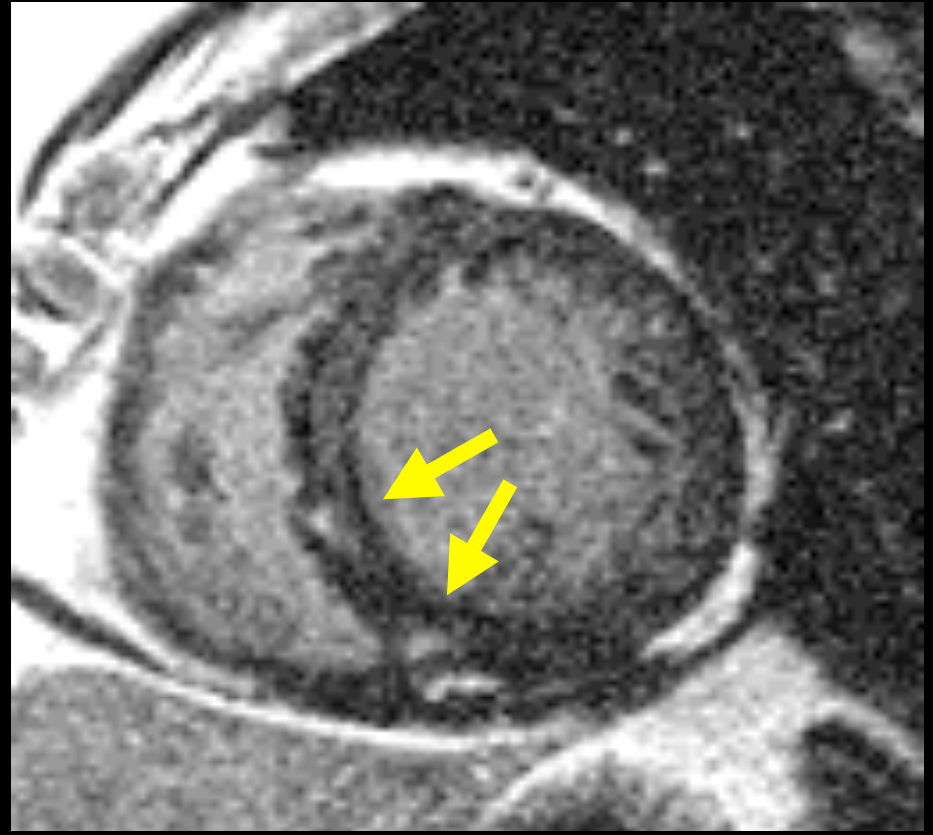
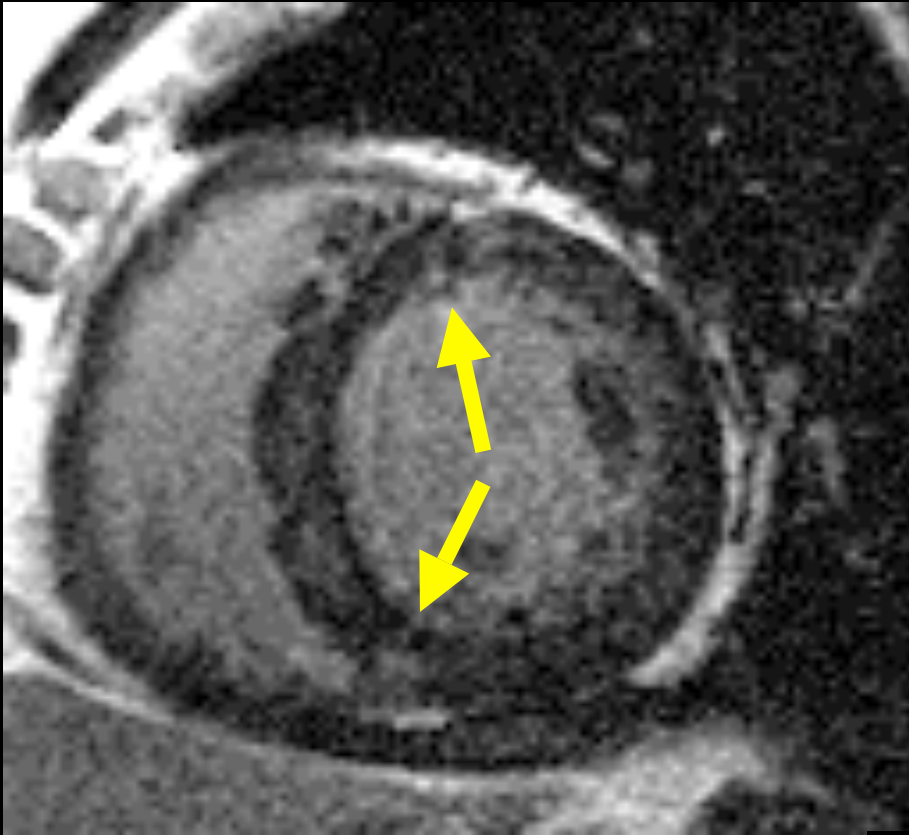
Delayed Enhancement

? before function abnormal



Delayed Enhancement

target endomyocardial bx



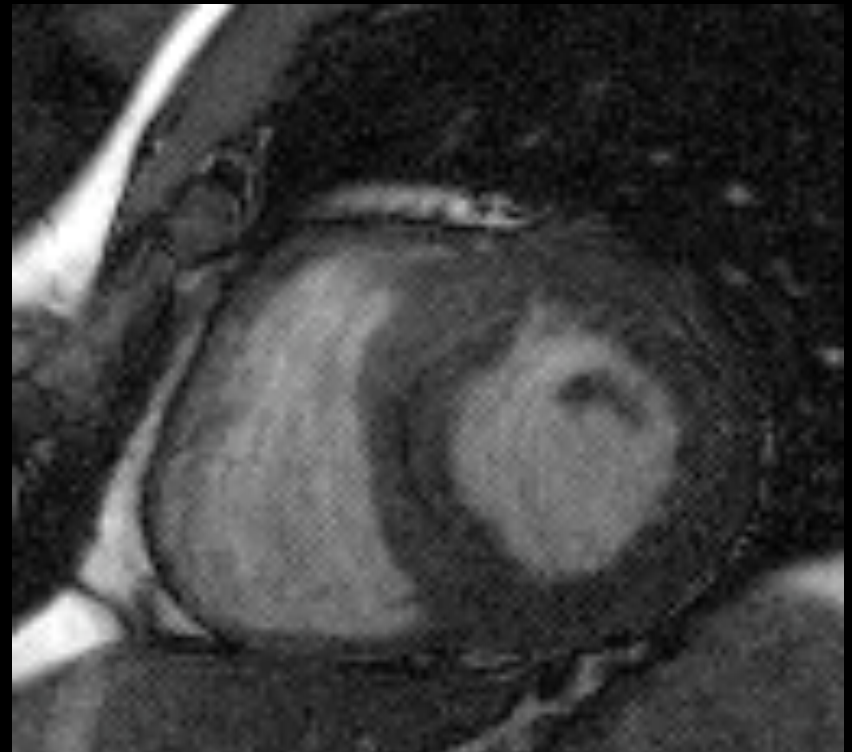
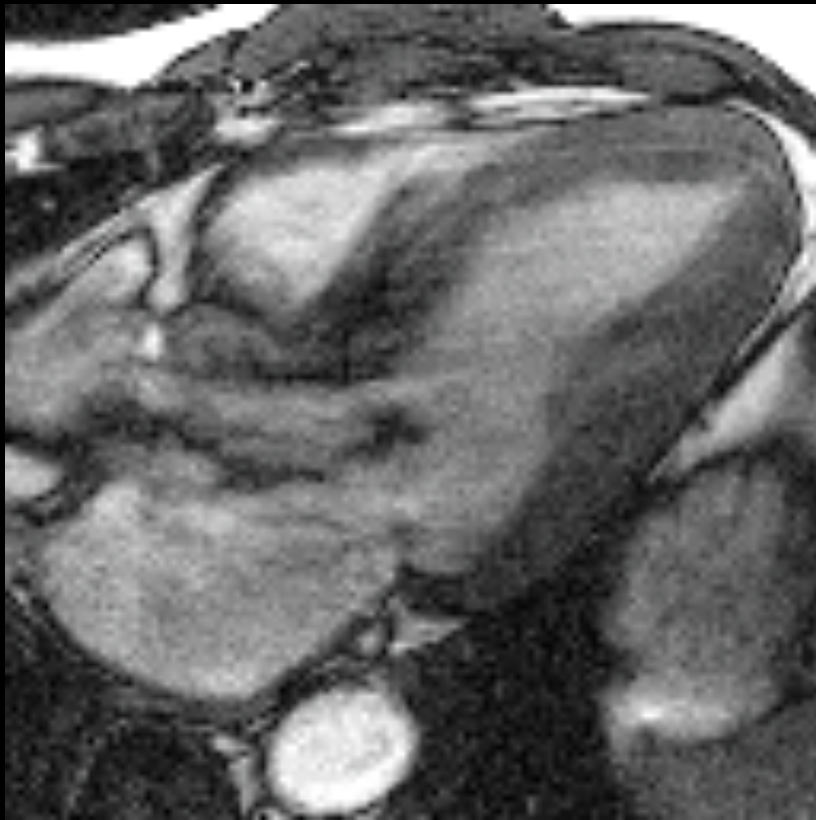
Sudden Death in Young Patient

- Cardiac sarcoid
- **Hypertrophic CM**
- Arrhythmogenic RV dysplasia
- Anomalous coronary

Hypertrophic Cardiomyopathy

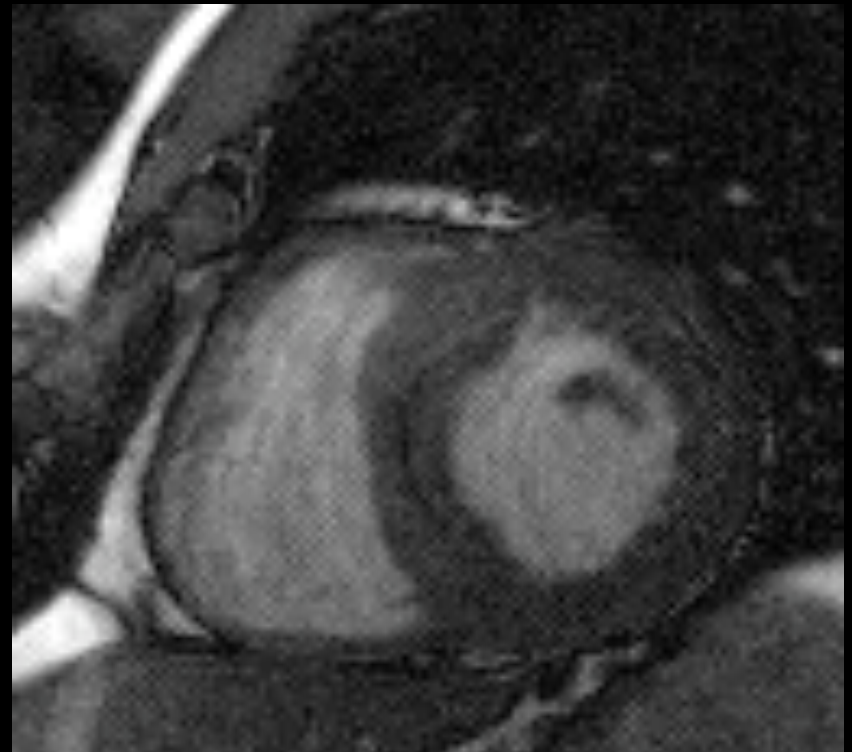
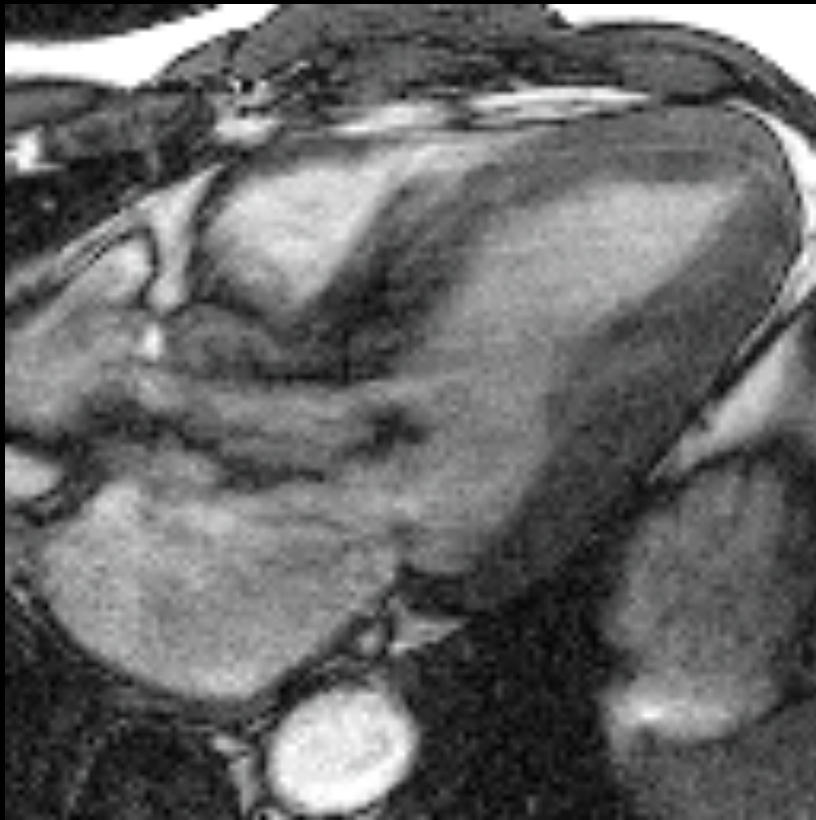
- **LV hypertrophy, no cause**
- **Genetic**
- **Sudden death:
arrhythmia, LVOT obstruction**

Hypertrophic Cardiomyopathy: Wall thickness $> 1\text{cm}$



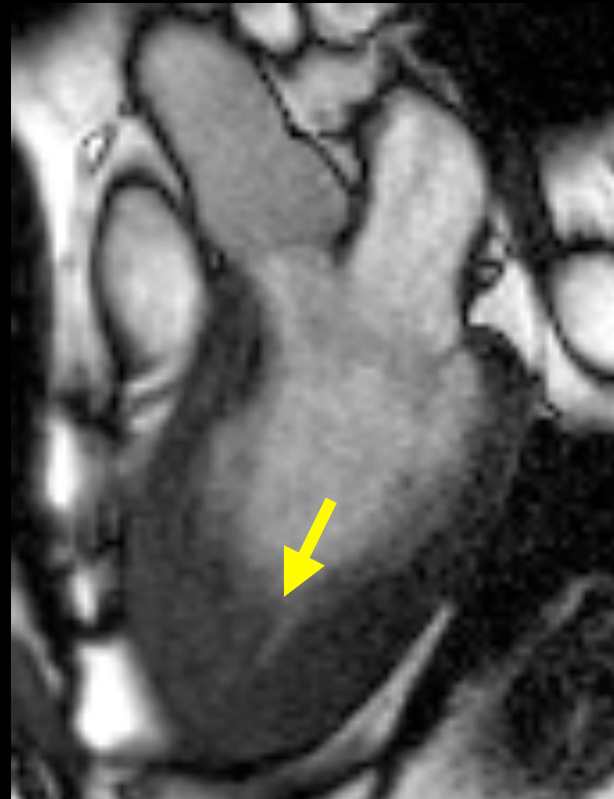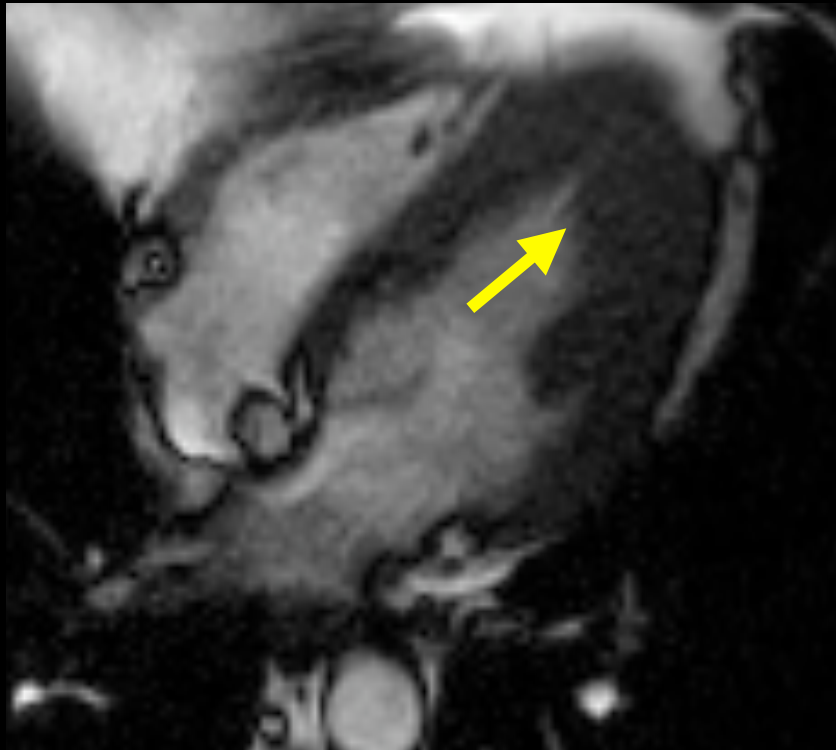
N Engl J Med 2004; 350:1320-1327

Hypertrophic Cardiomyopathy: Concentric hypertrophy

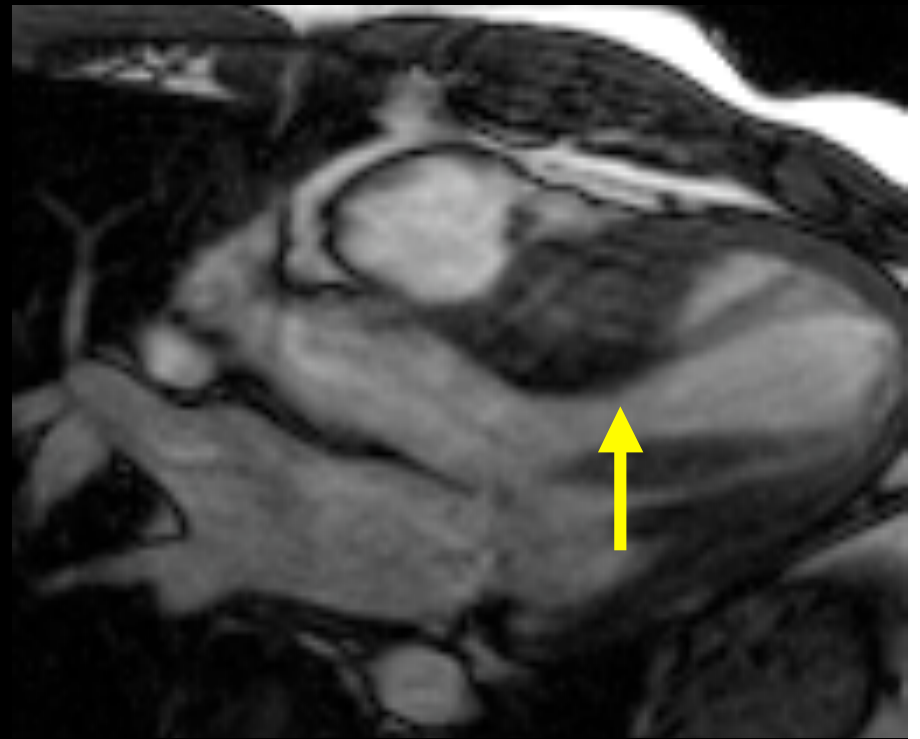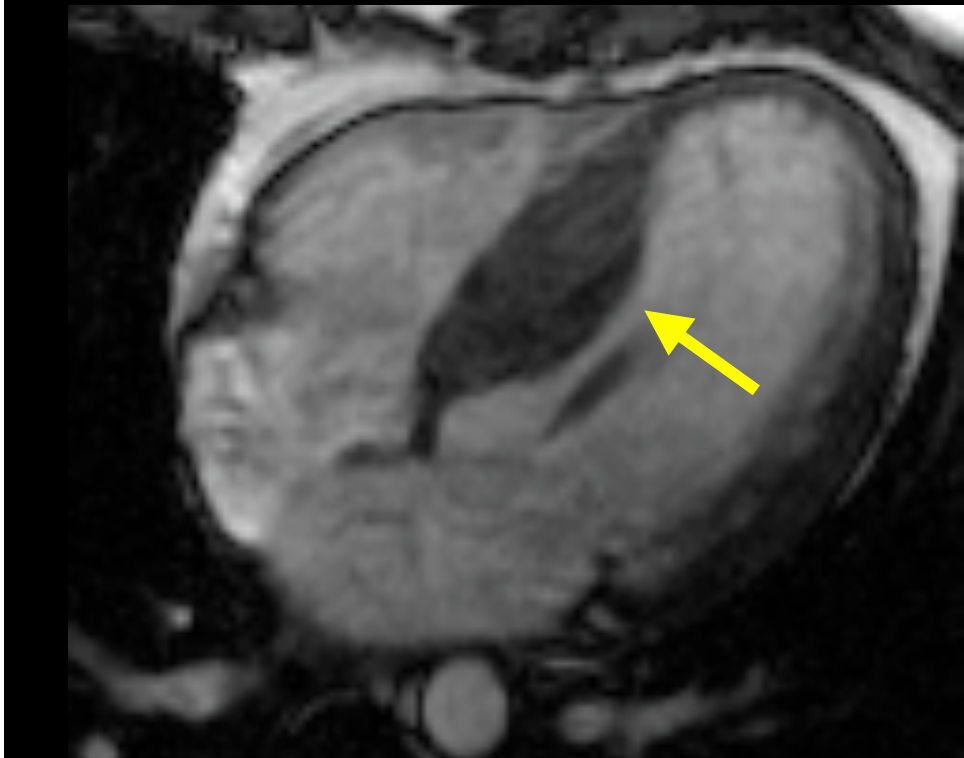


N Engl J Med 2004; 350:1320-1327

Hypertrophic Cardiomyopathy: Asymmetric: apical



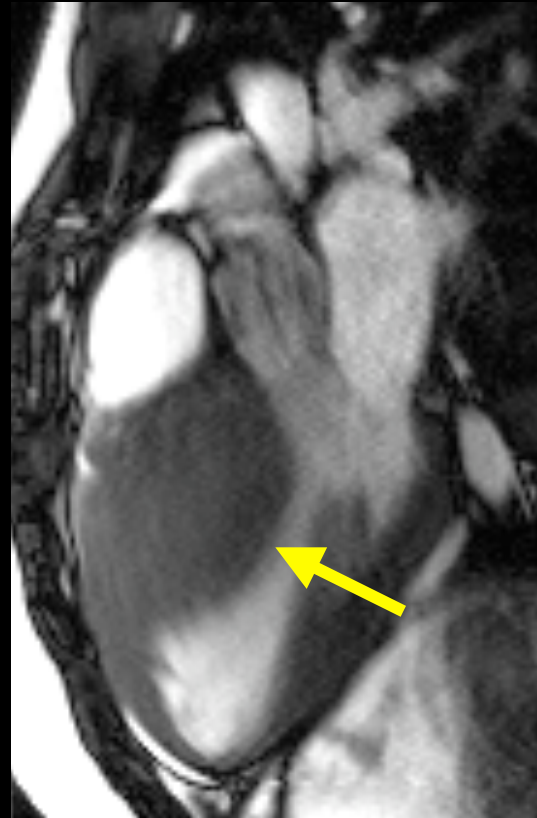
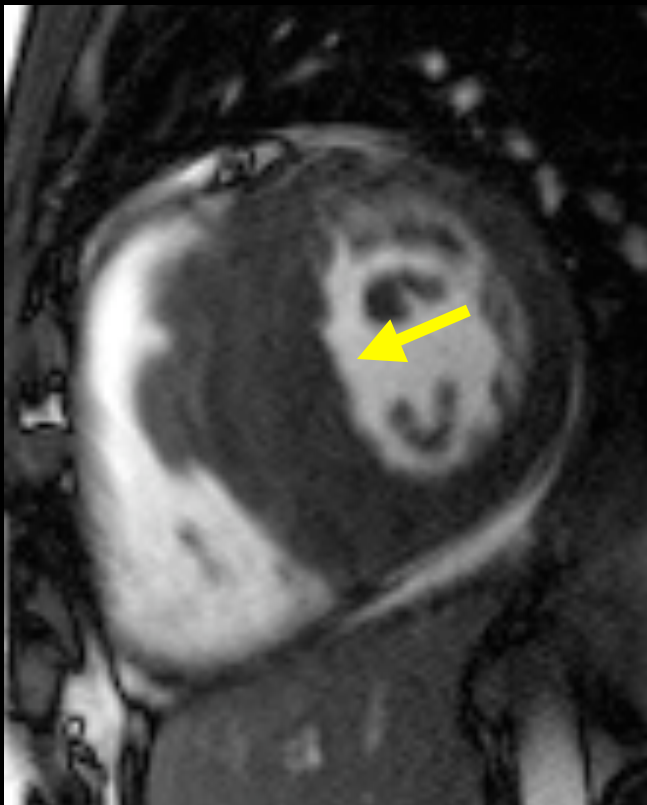
Hypertrophic Cardiomyopathy: Asymmetric: septal



N Engl J Med 2004; 350:1320-1327

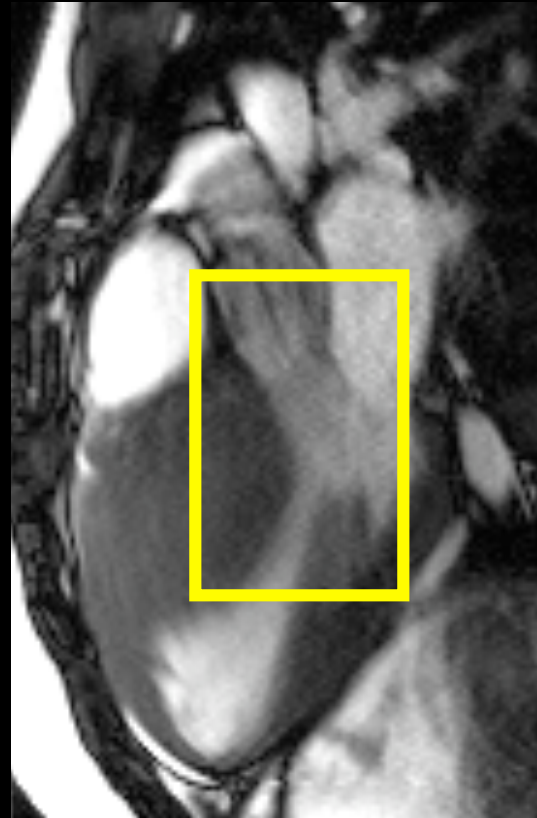
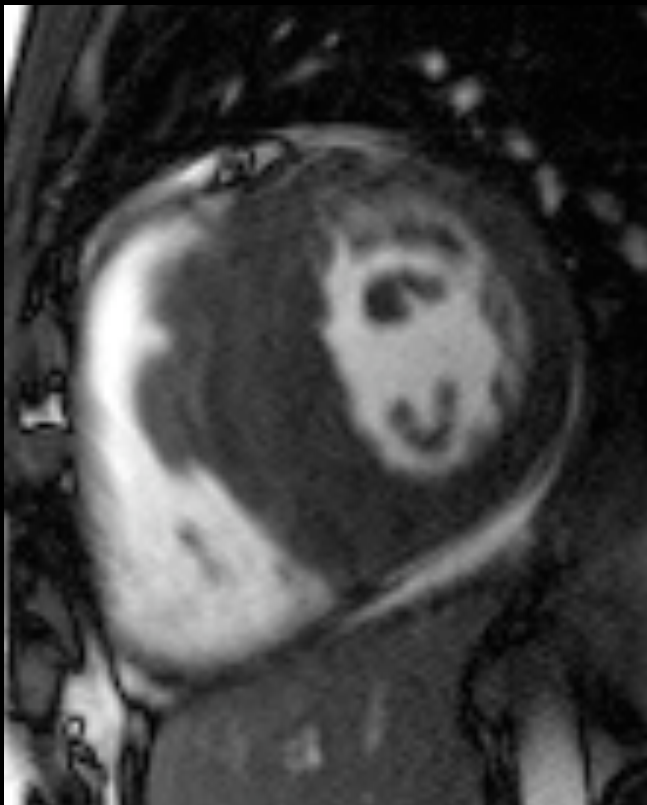
Hypertrophic Cardiomyopathy:

Septal: ?LVOT obstruction



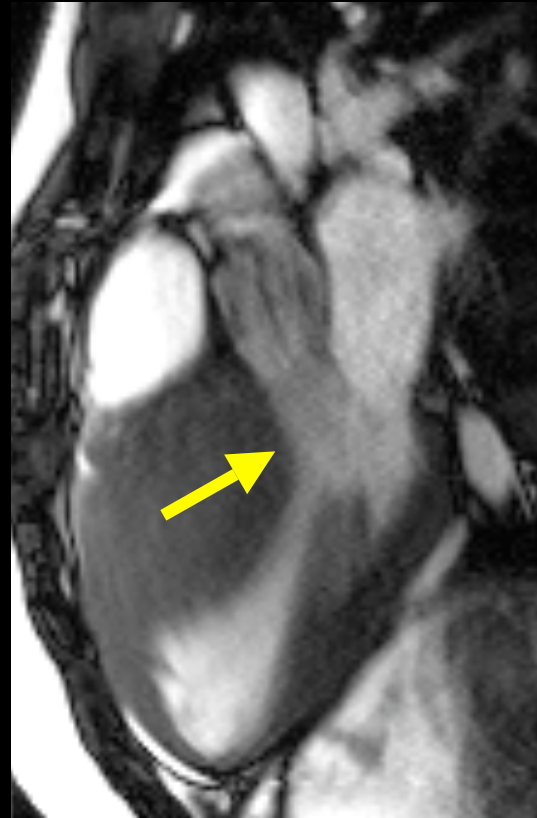
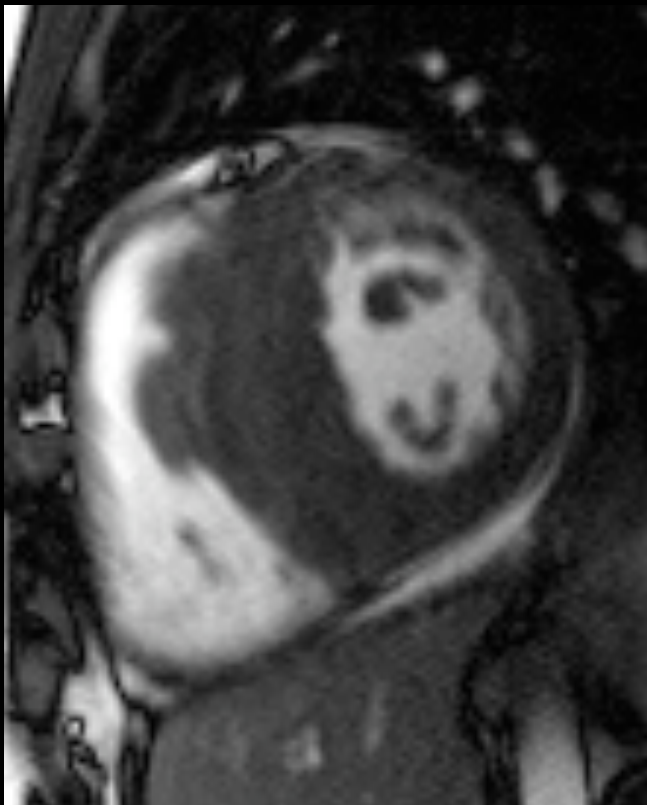
Hypertrophic Cardiomyopathy:

Septal: ?LVOT obstruction

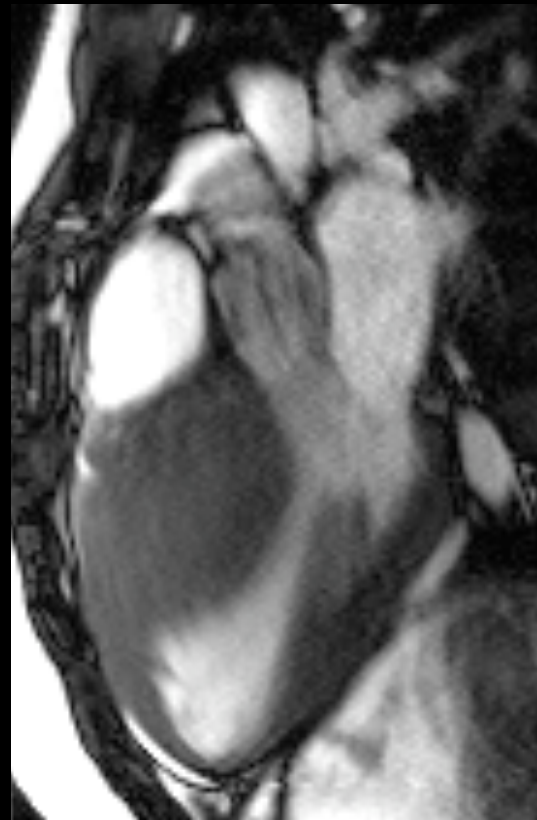
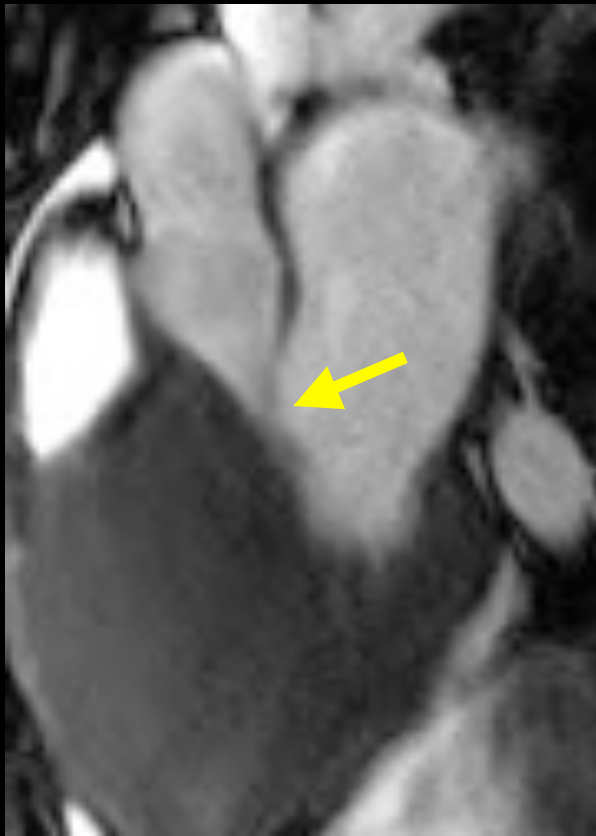


Hypertrophic Cardiomyopathy:

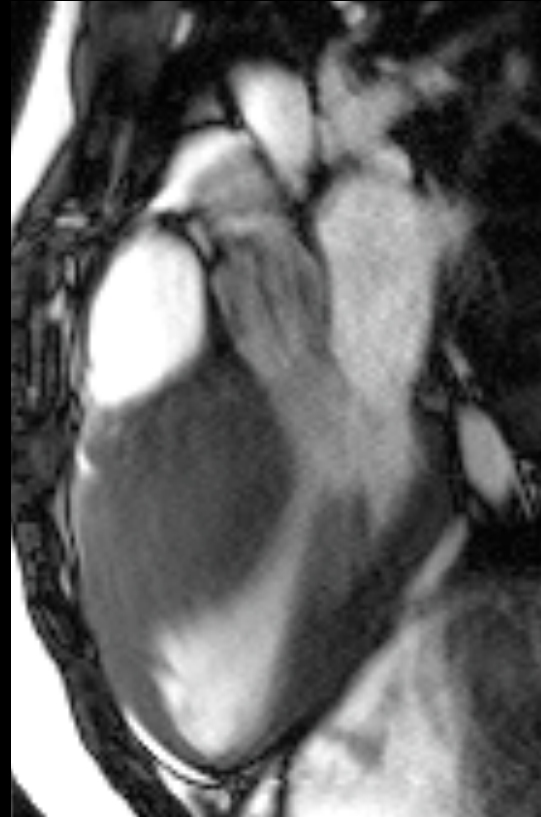
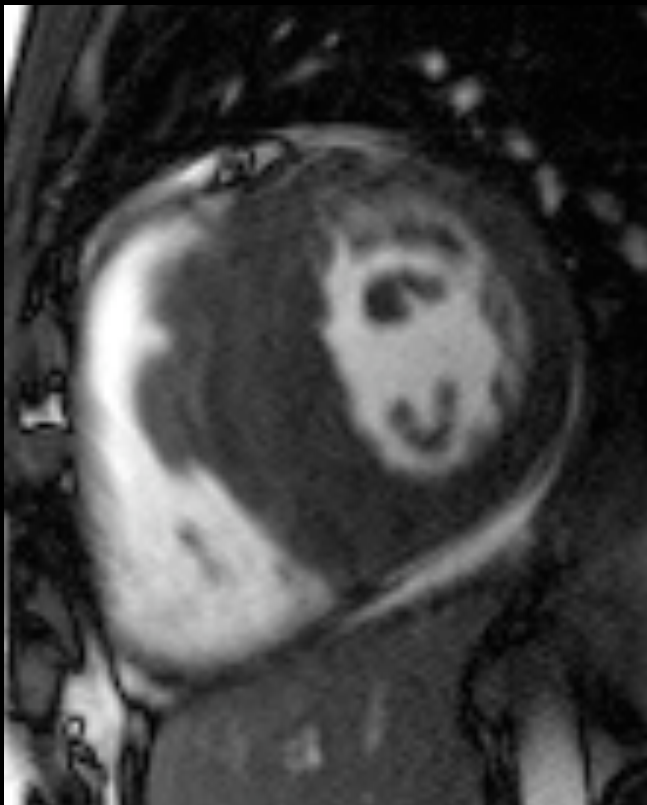
Jet / turbulent flow in LVOT



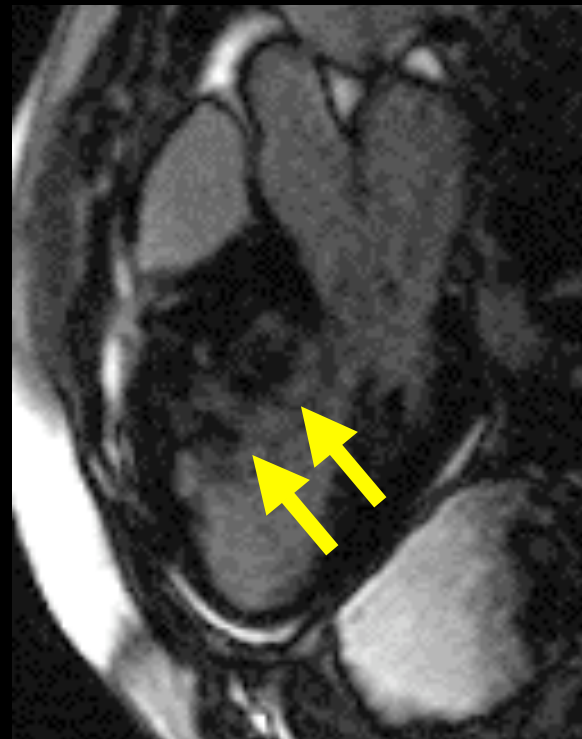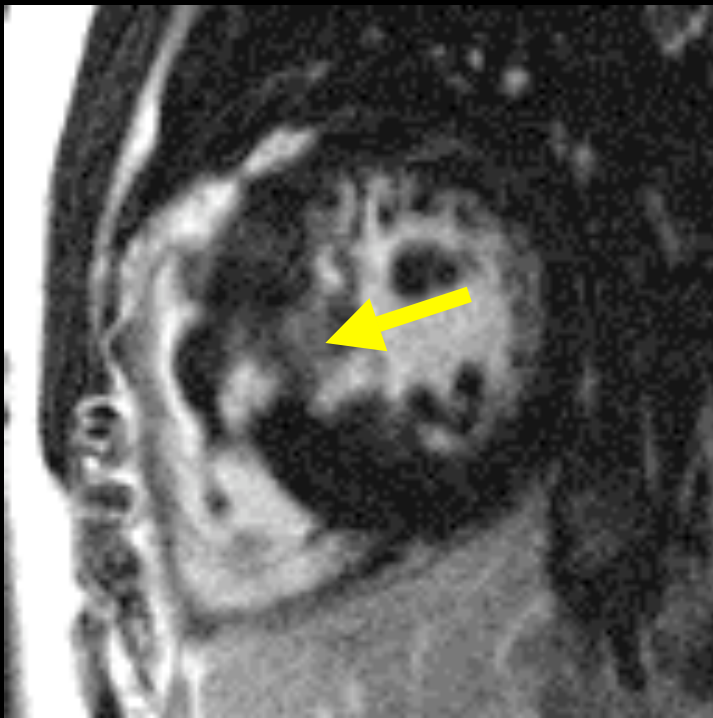
Characteristic SAM: Systolic Anterior Motion of anterior leaflet MV



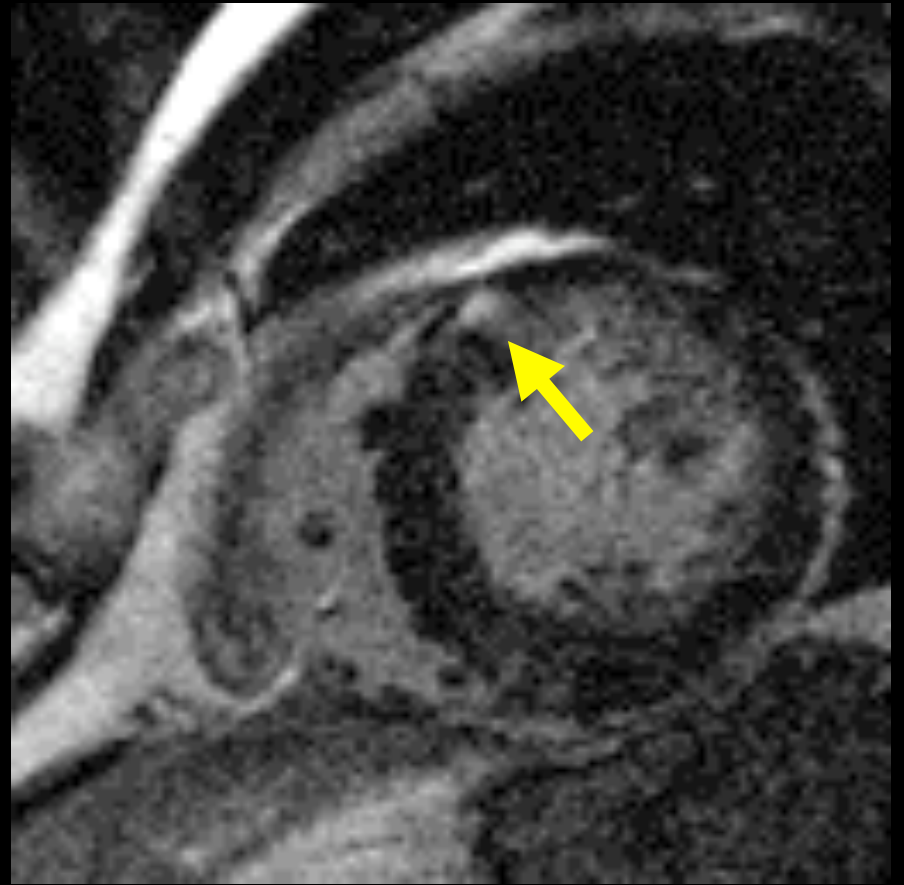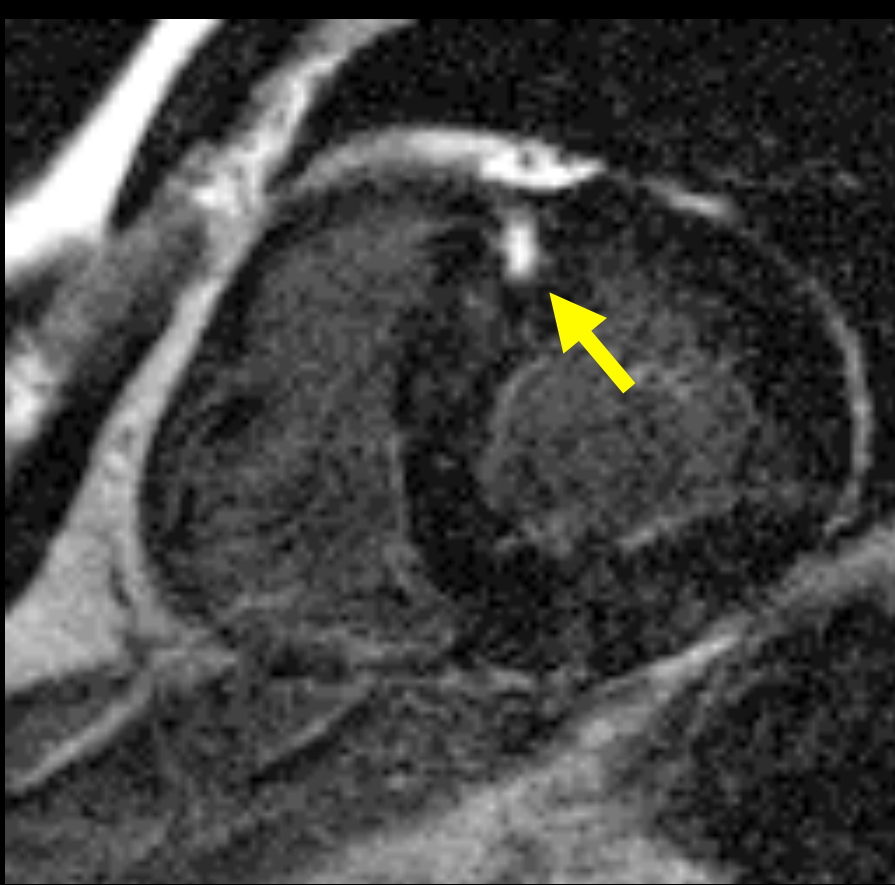
Hypertrophic Obstructive Cardiomyopathy (HOCM)



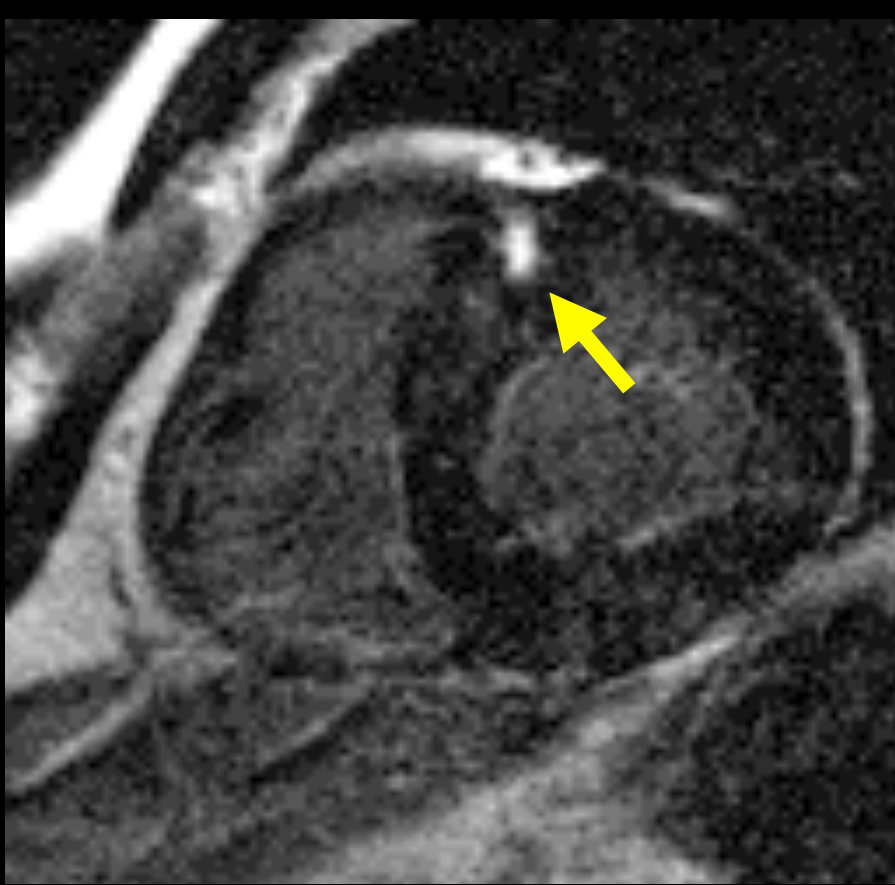
Delayed enhancement: patchy, midmyocardial



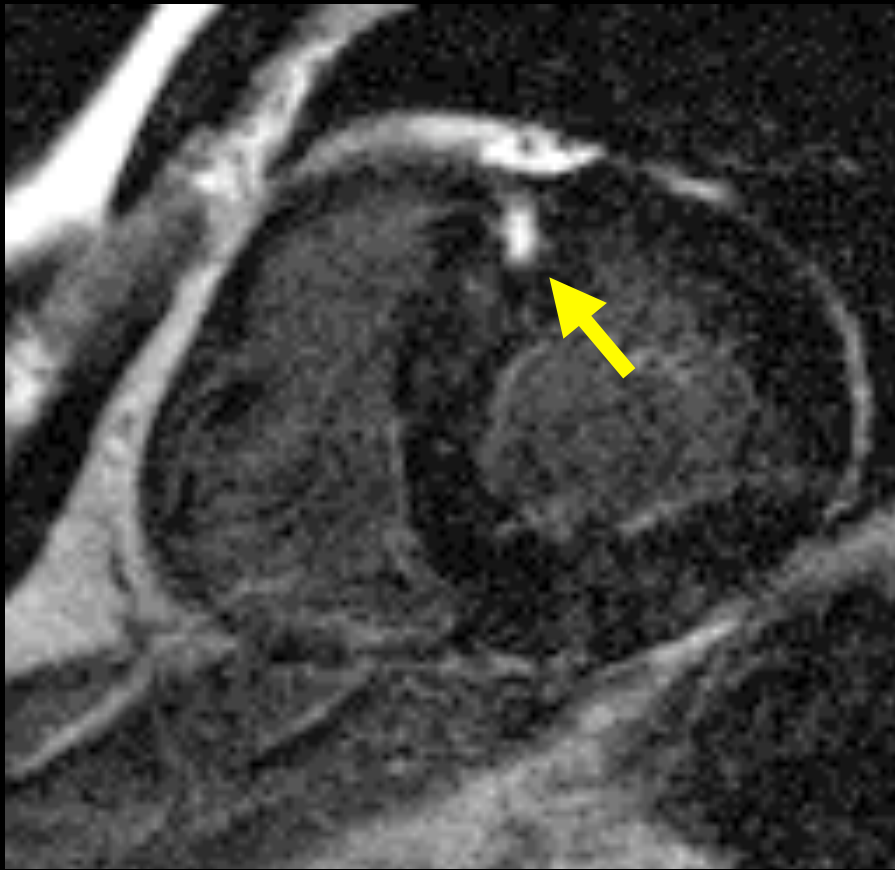
Delayed enhancement: jxn of septum, RV free wall



Delayed enhancement: 81% HCM patients: + scar



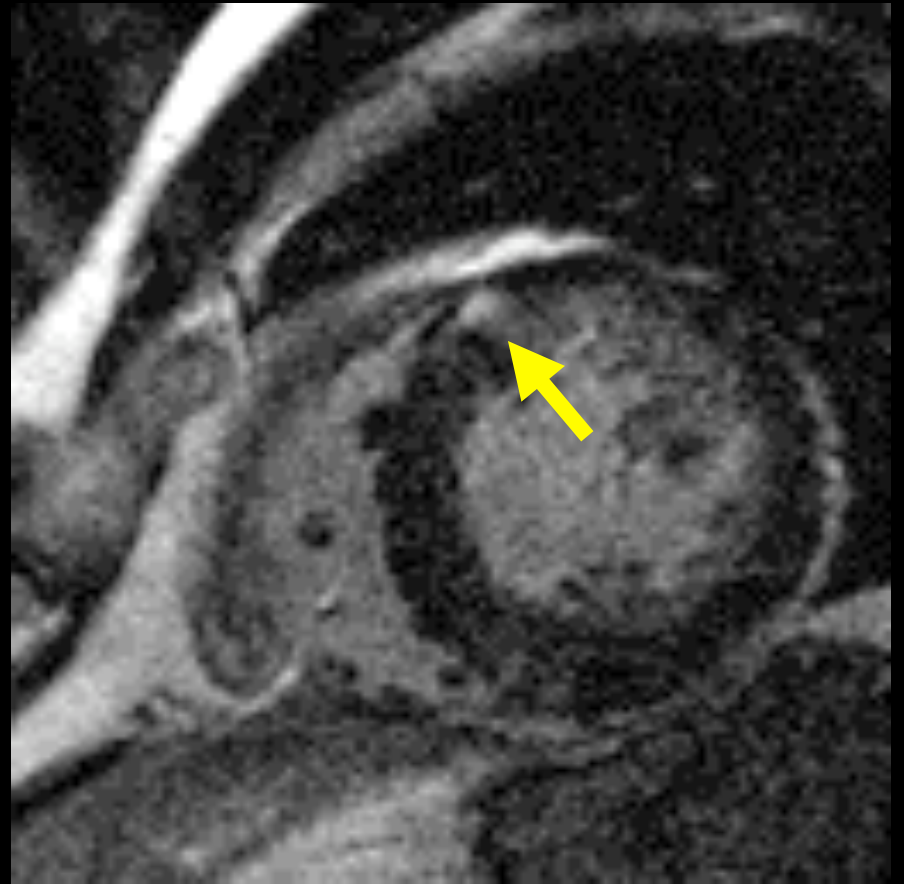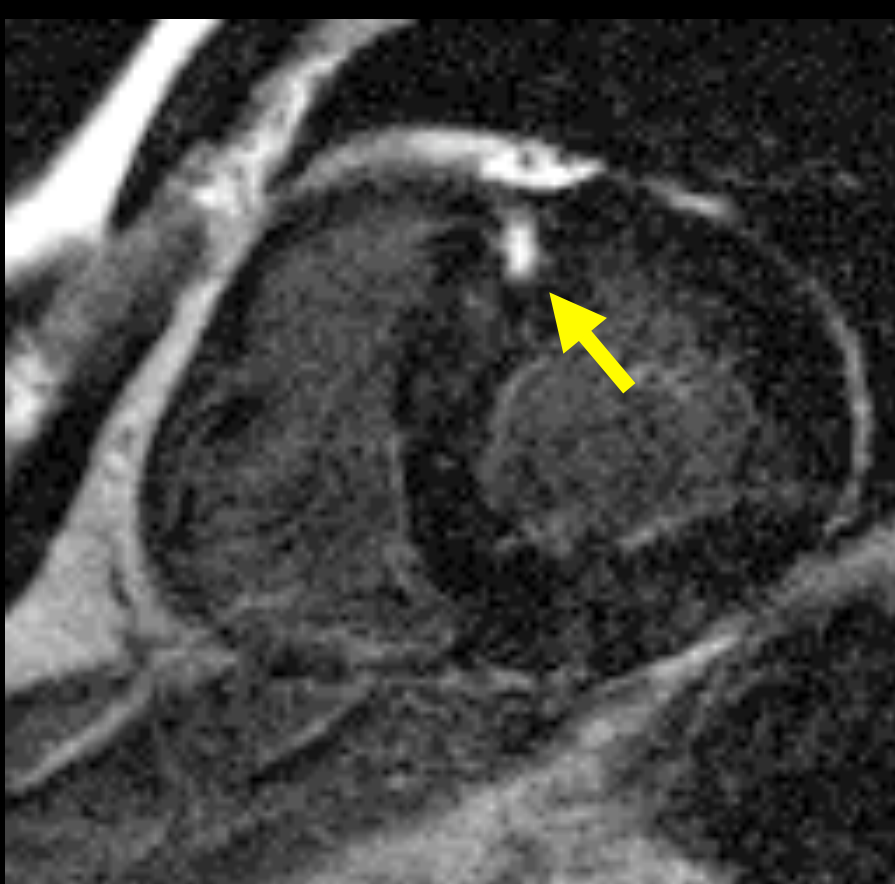
Delayed enhancement: + collagen; ? ischemia



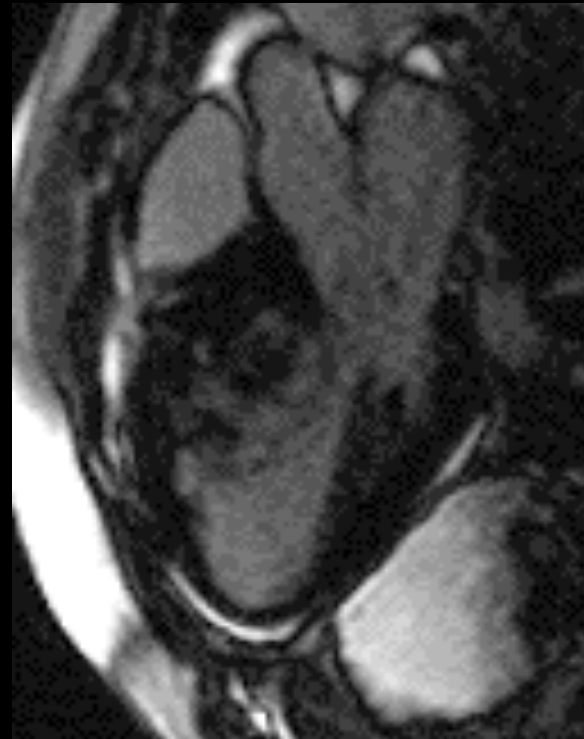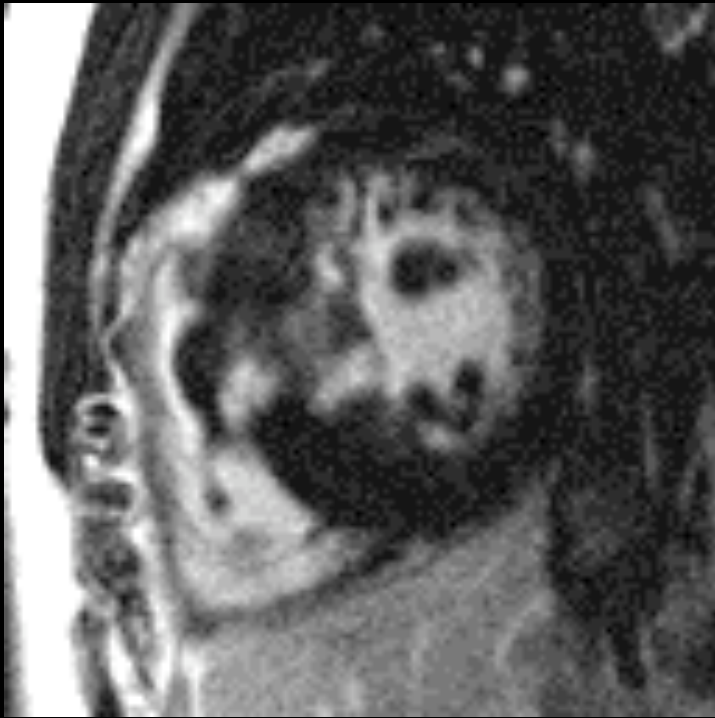J Am Coll Cardiol 1986; 8 (3):545-557.

J Am Coll Cardiol 2004; 43 (12):2260-4.

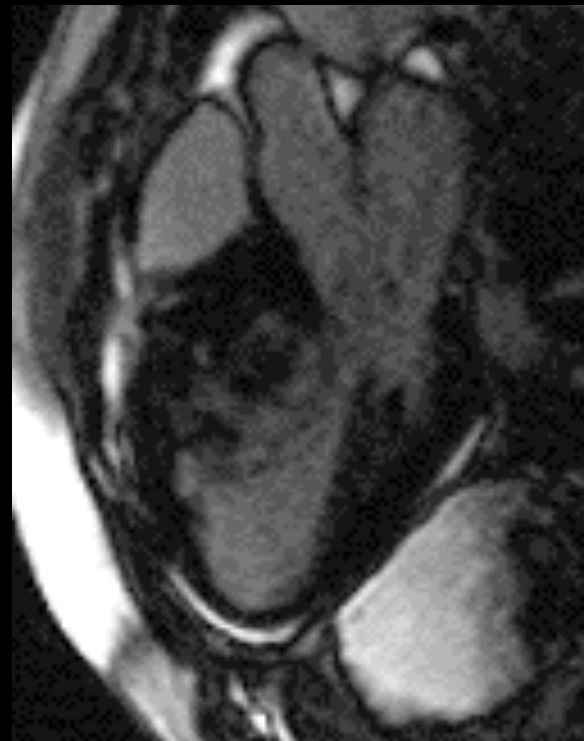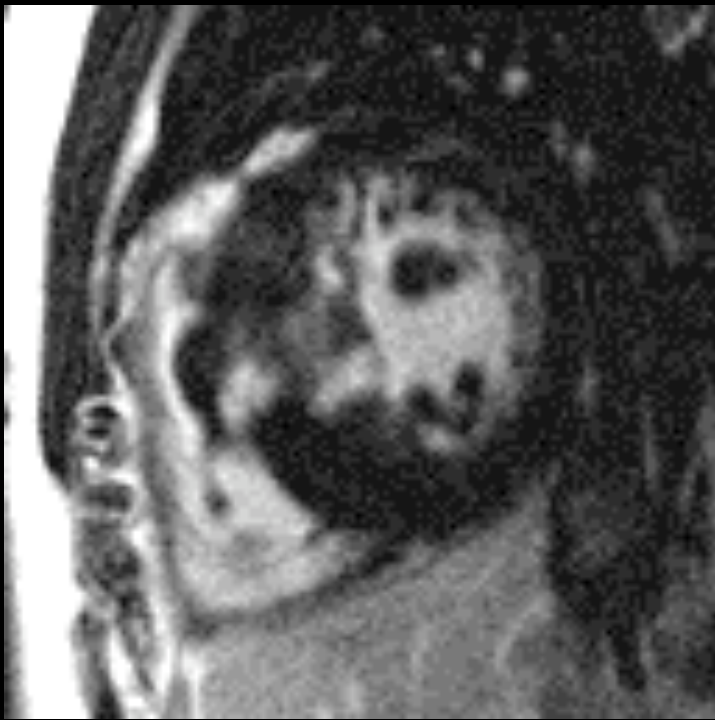Delayed enhancement: ? arrhythmogenic foci



Delayed enhancement: ? ↑ scar: ↑ risk SCD ?

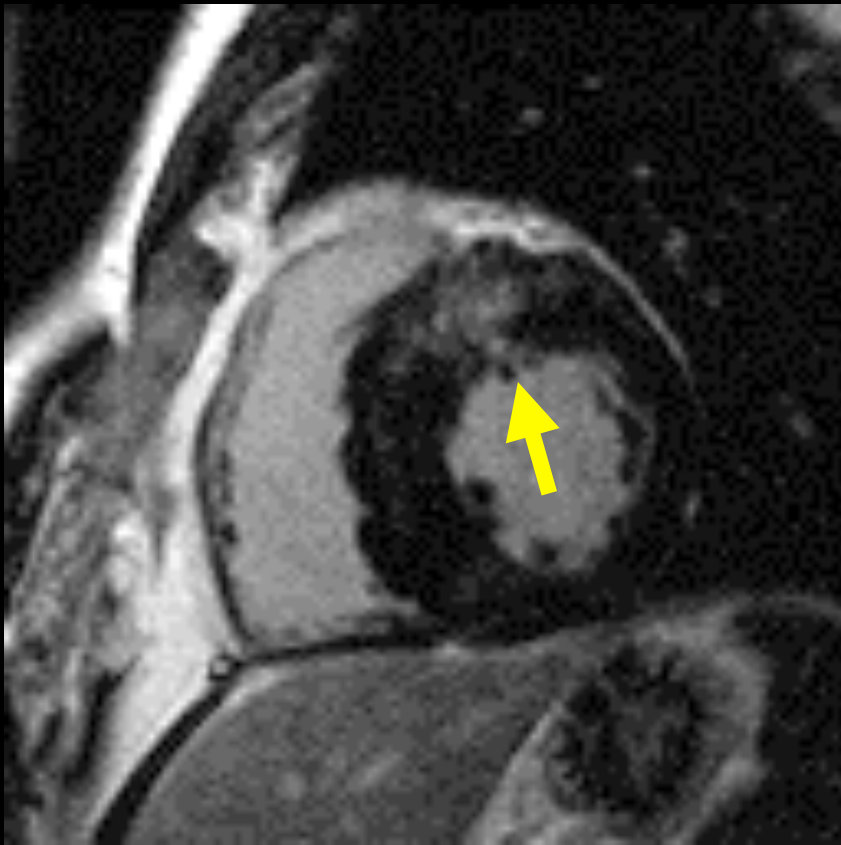


Delayed enhancement: LVDT > 3 cm; ↑ risk SCD



J Am Society Echocardiogr 2006; 19(6): 788-795.

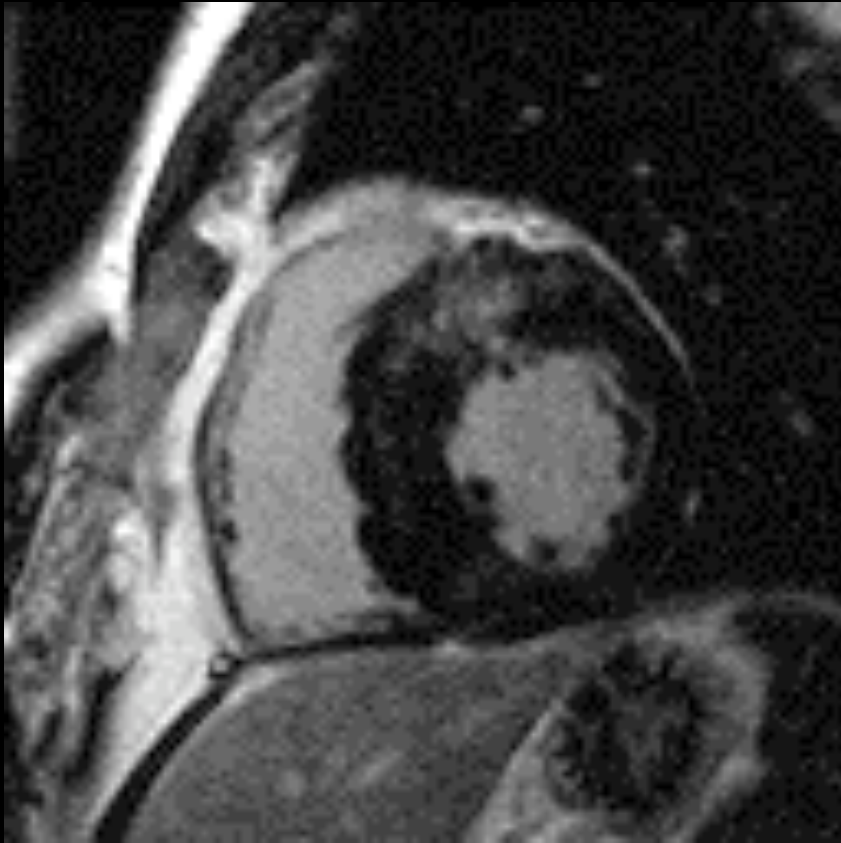
Treatment for HOCM: EtOH ablation



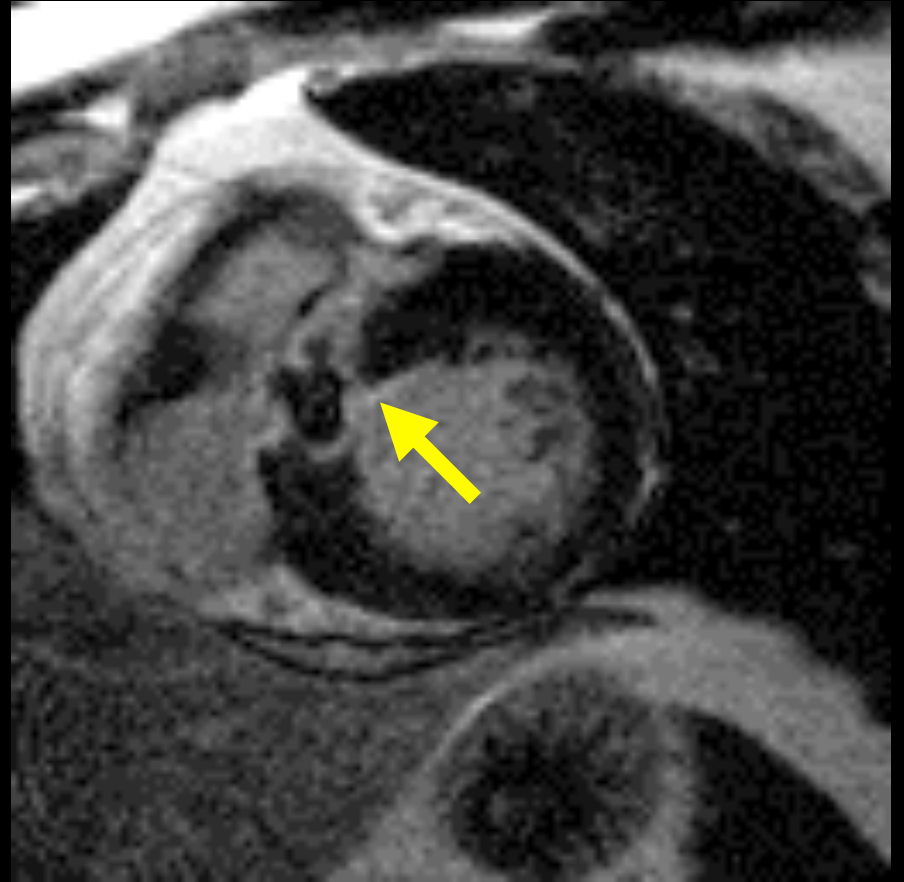
Pre ablation

J Am Coll Cardiol 2004; 43(1):27-34.

Treatment for HOCM: EtOH ablation

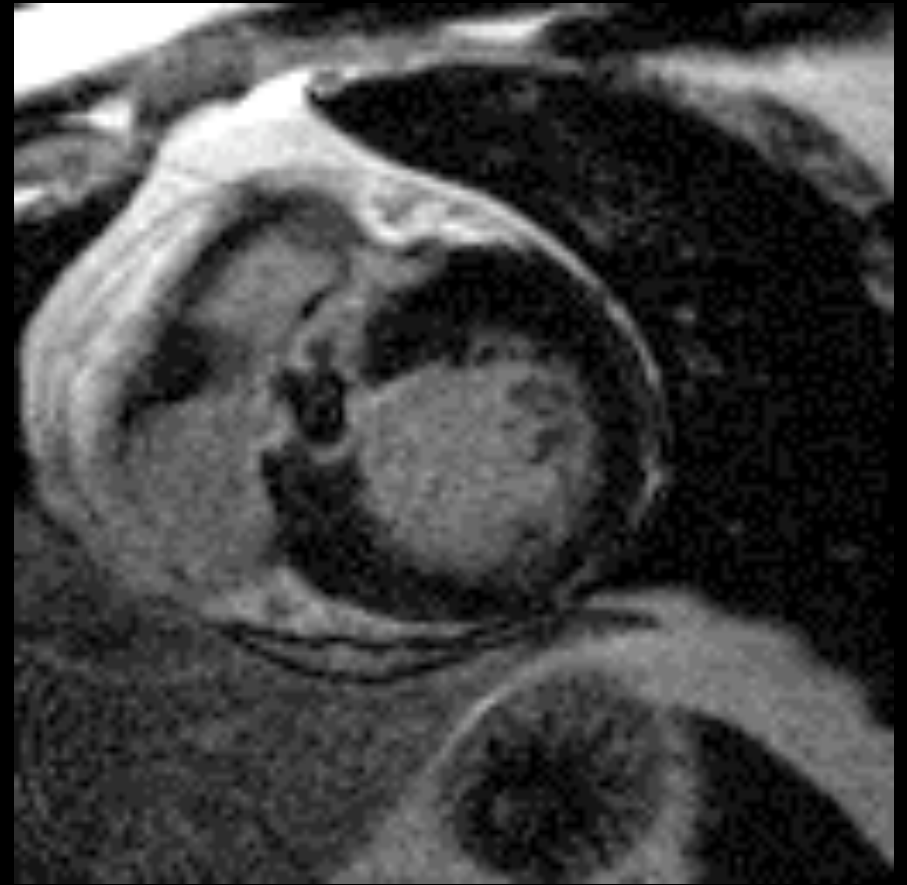
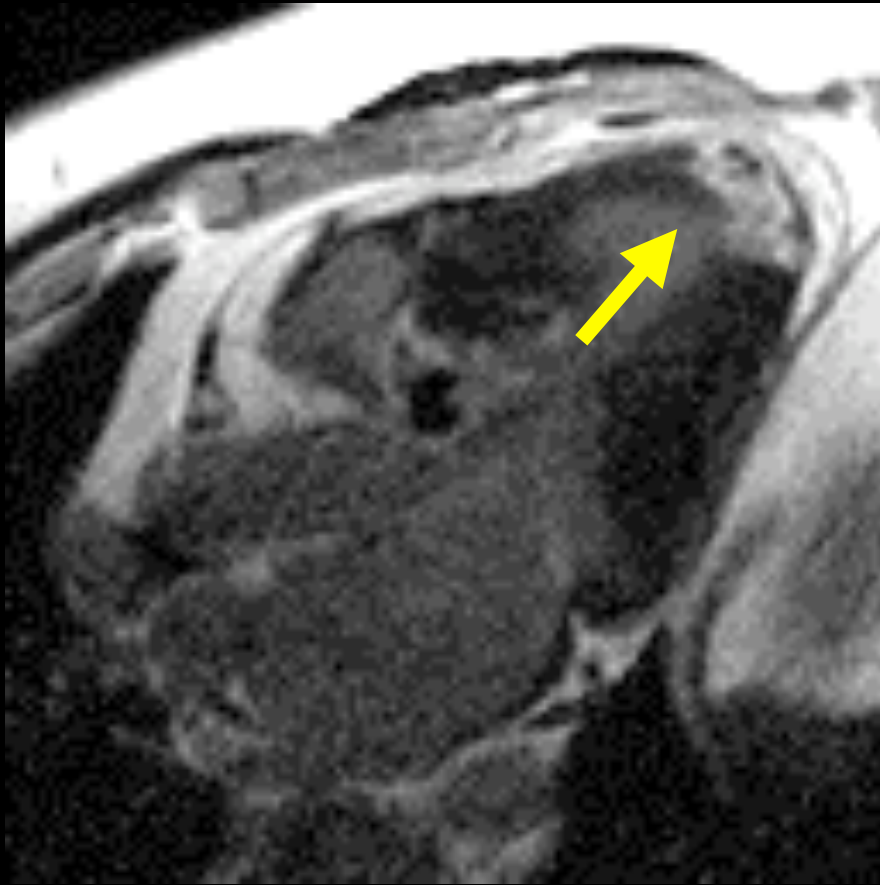


Pre ablation



Post ablation

Treatment for HOCM: EtOH ablation

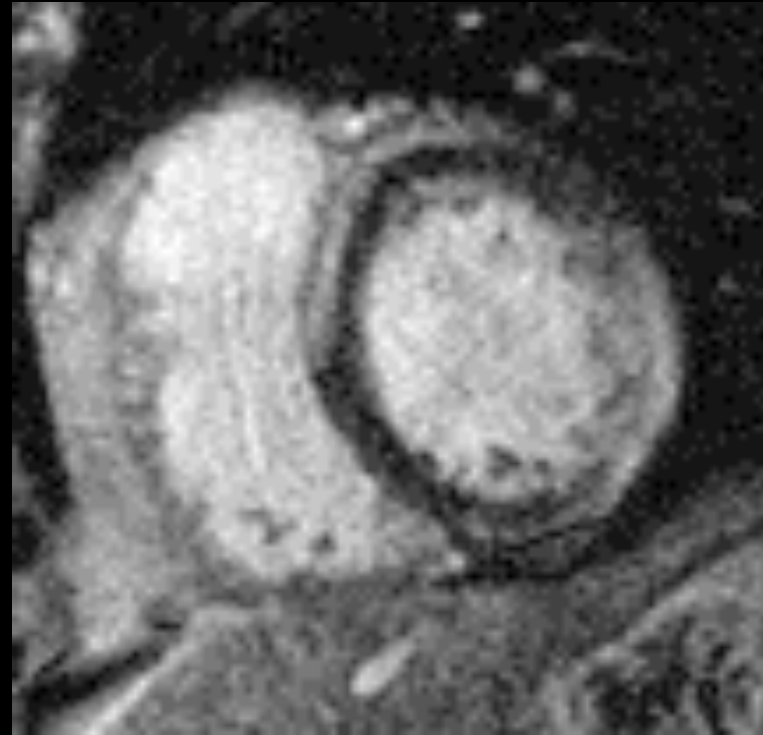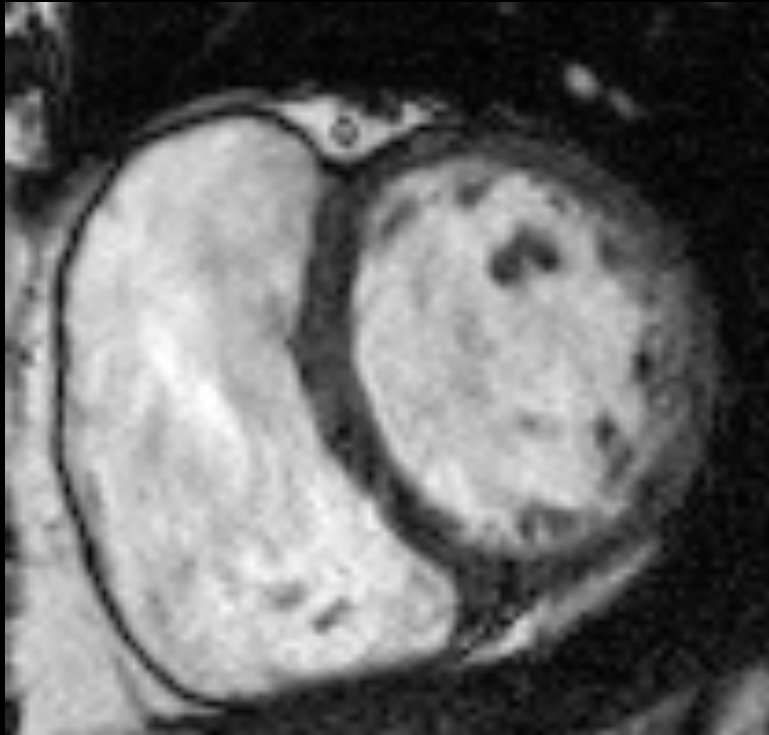


LAD infarction post ablation

Laura E. Heyneman, MD
heyne001@mc.duke.edu
www.radiologytalks.com

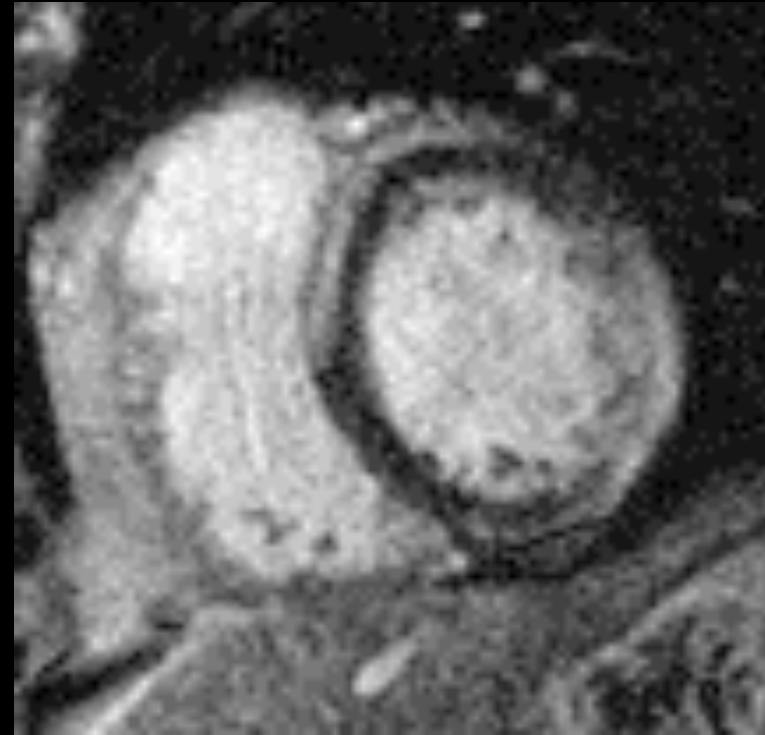
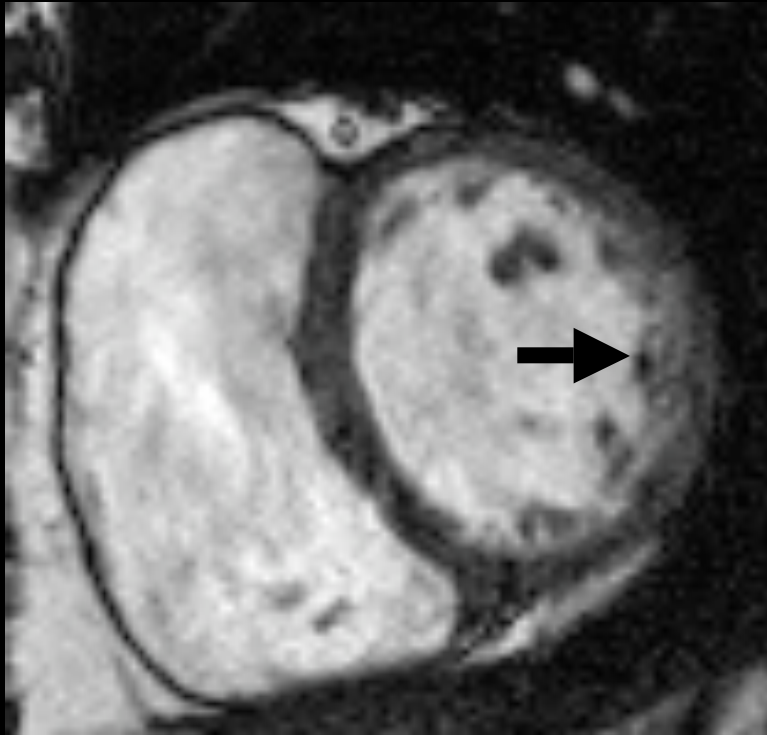
Unknown case 1

45 yo, arrhythmia

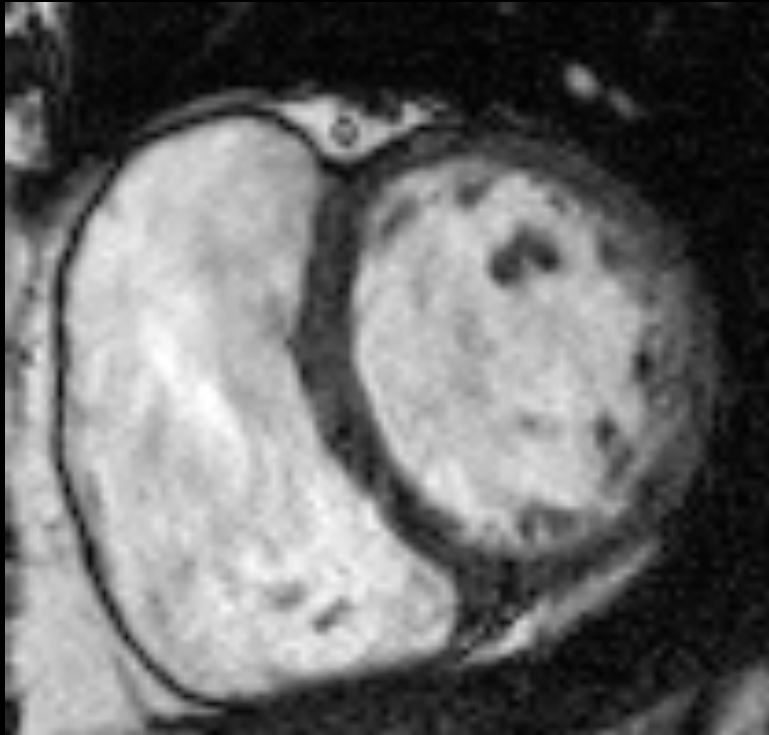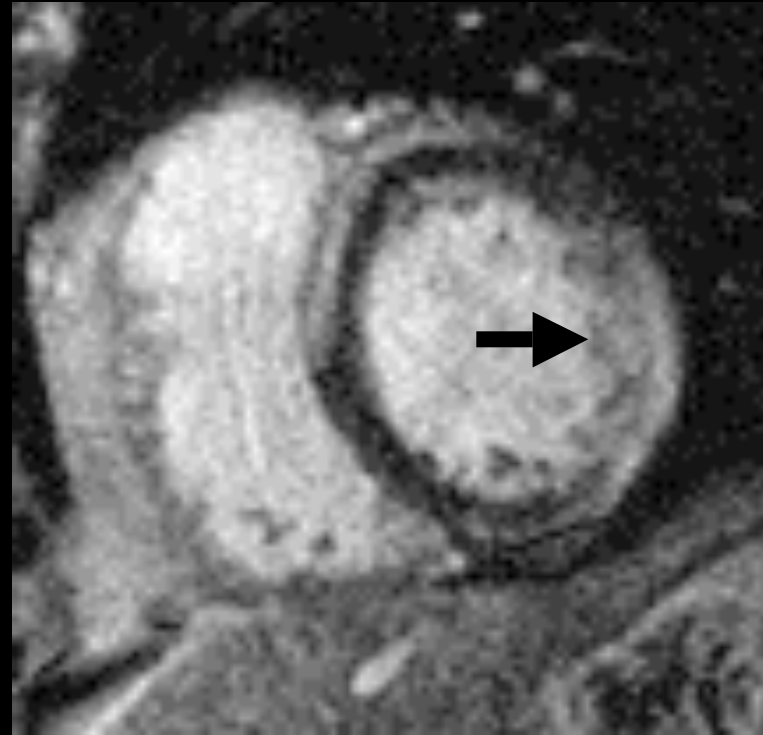


**Delayed
enhancement**

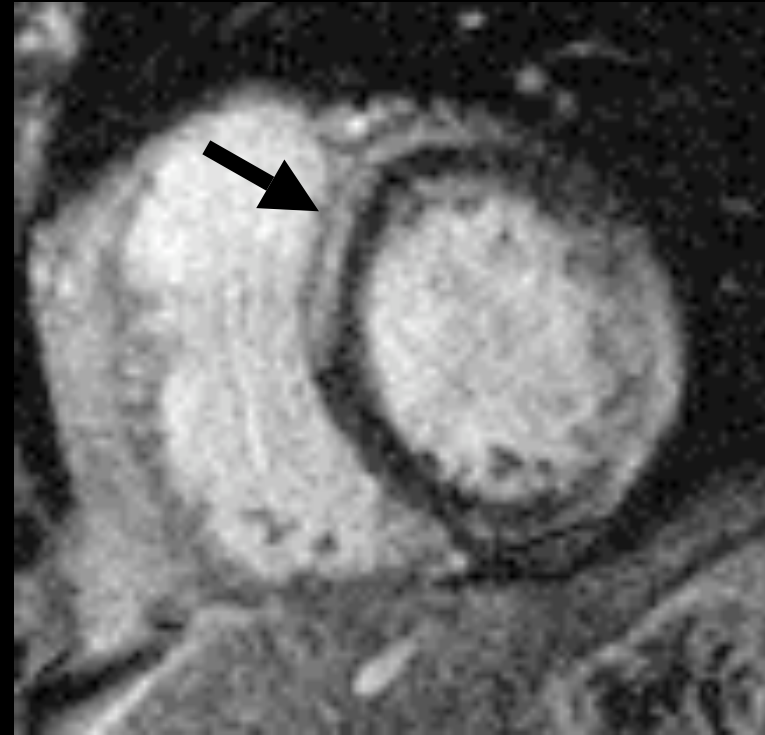
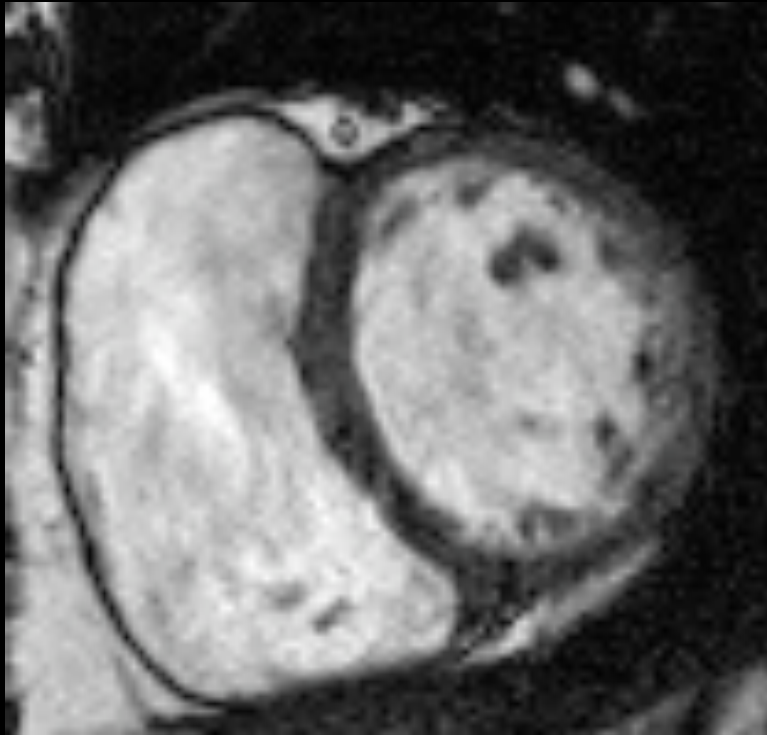
Lateral wall dyskinesia



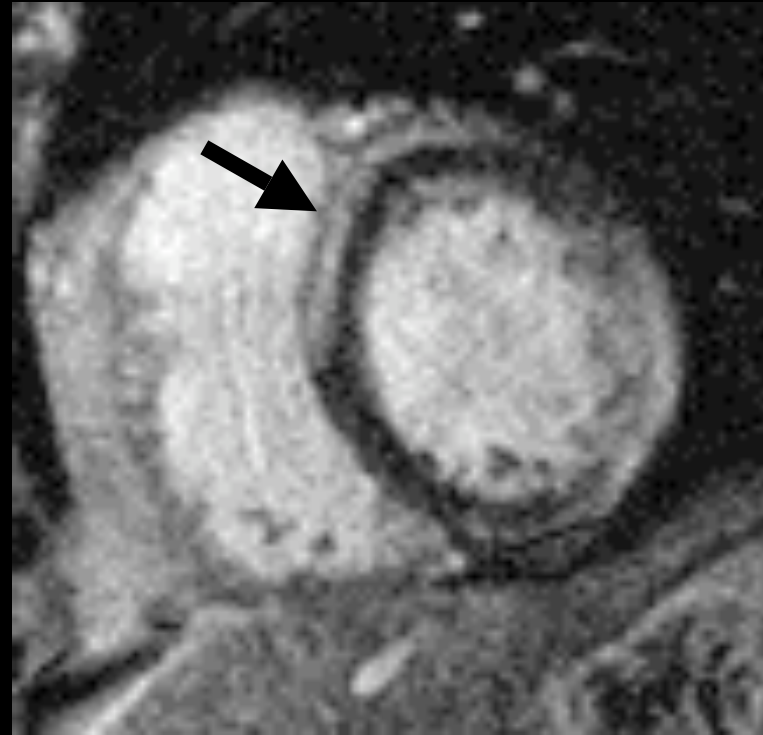
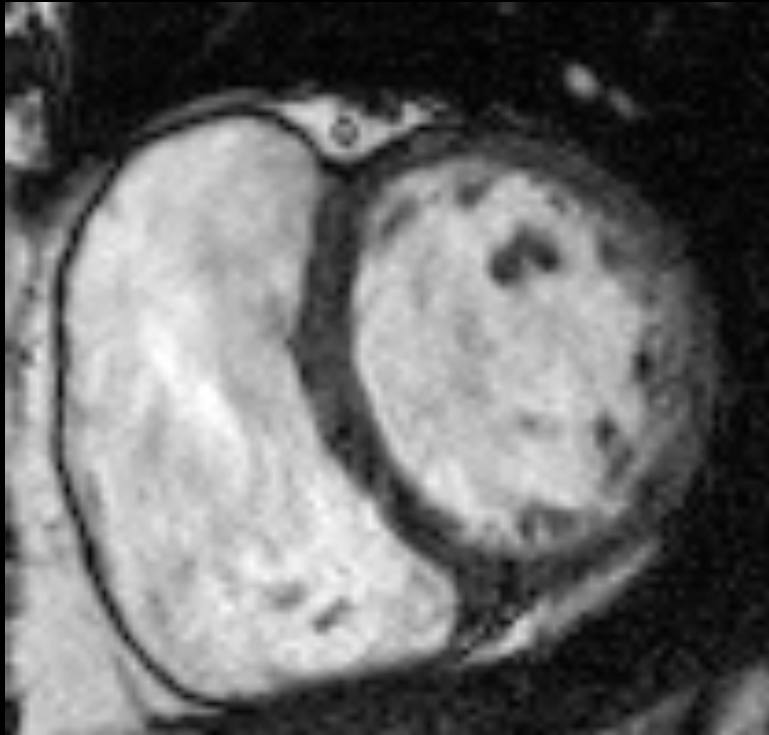
Transmural enhancement



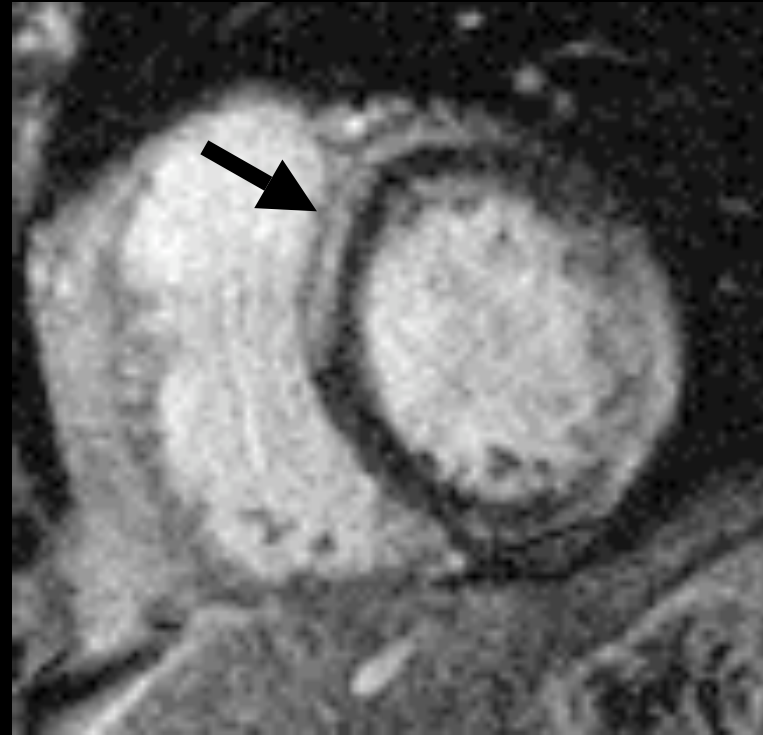
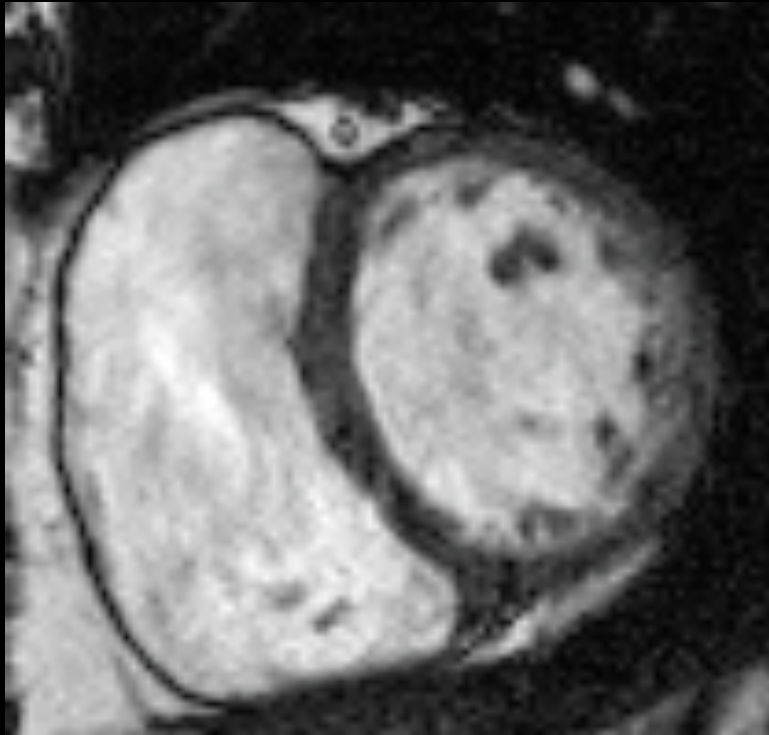
Epicardial enhancement



Epicardial enhancement: nonischemic cardiomyopathy



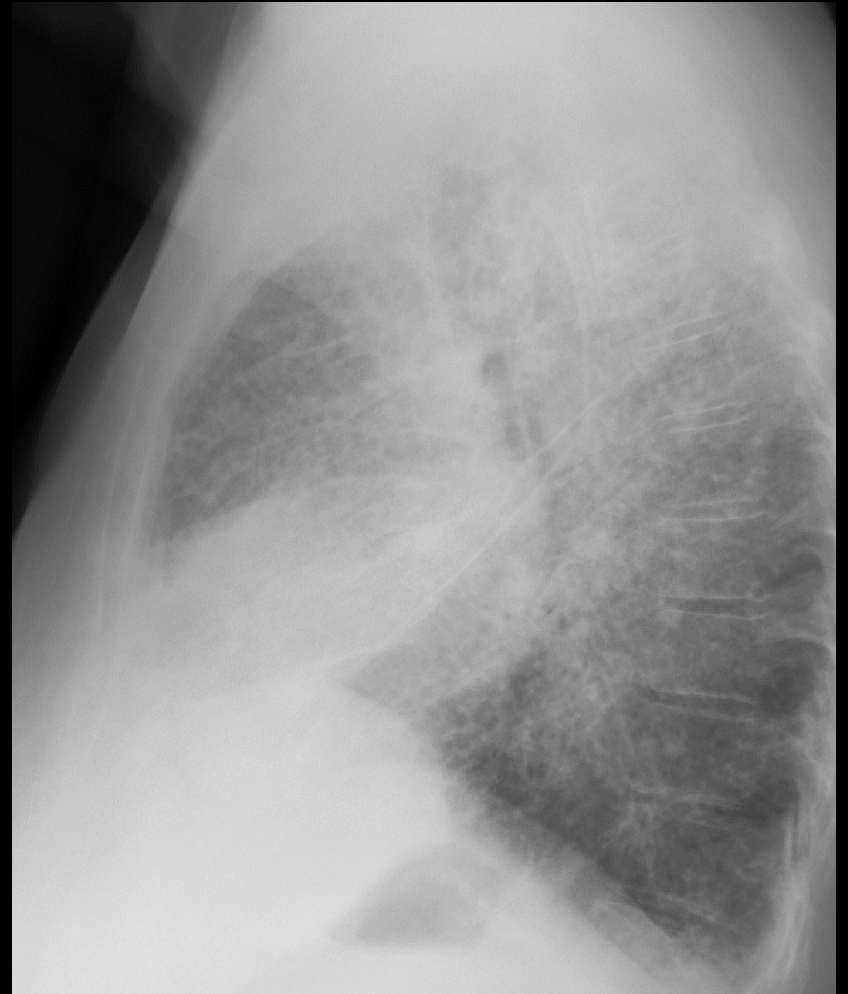
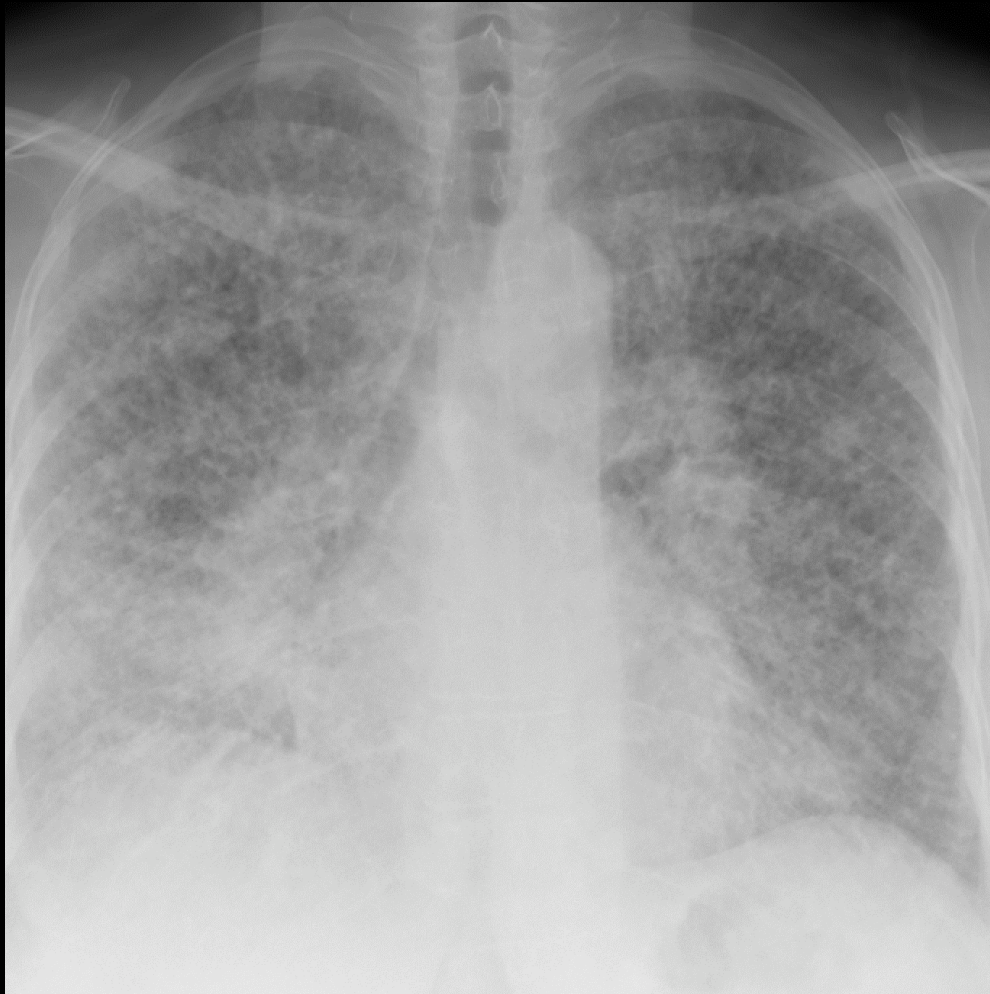Nonischemic cardiomyopathy: ? sarcoid, ? myocarditis



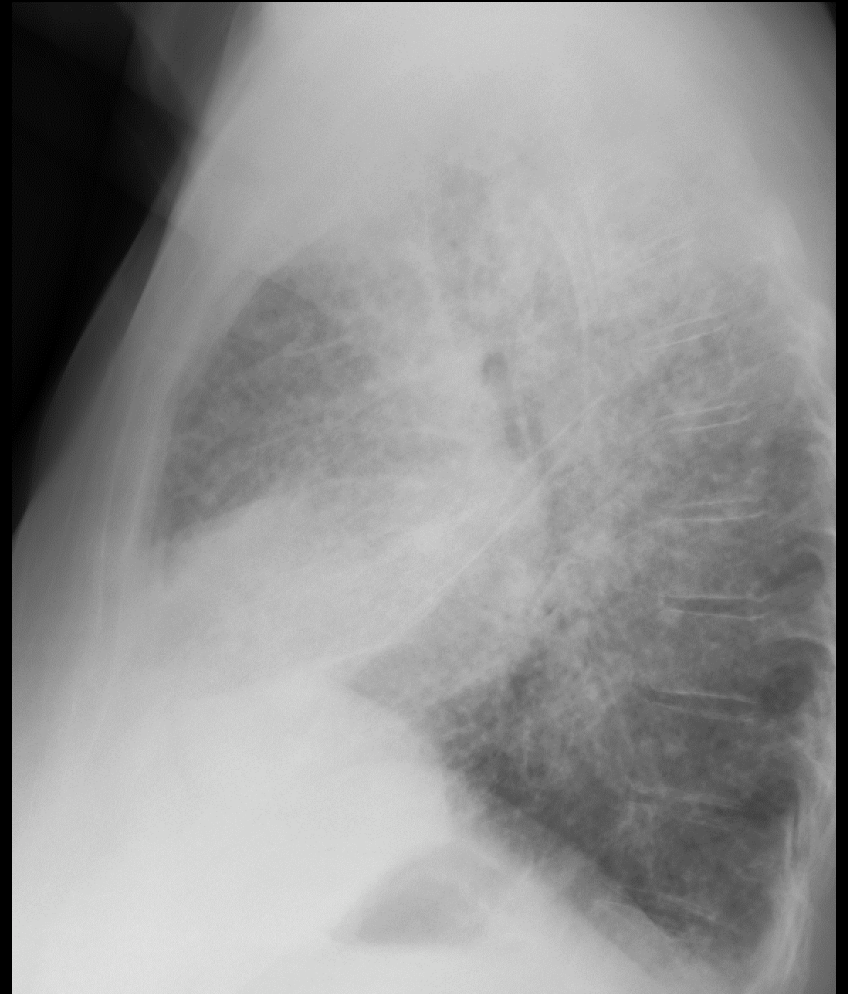
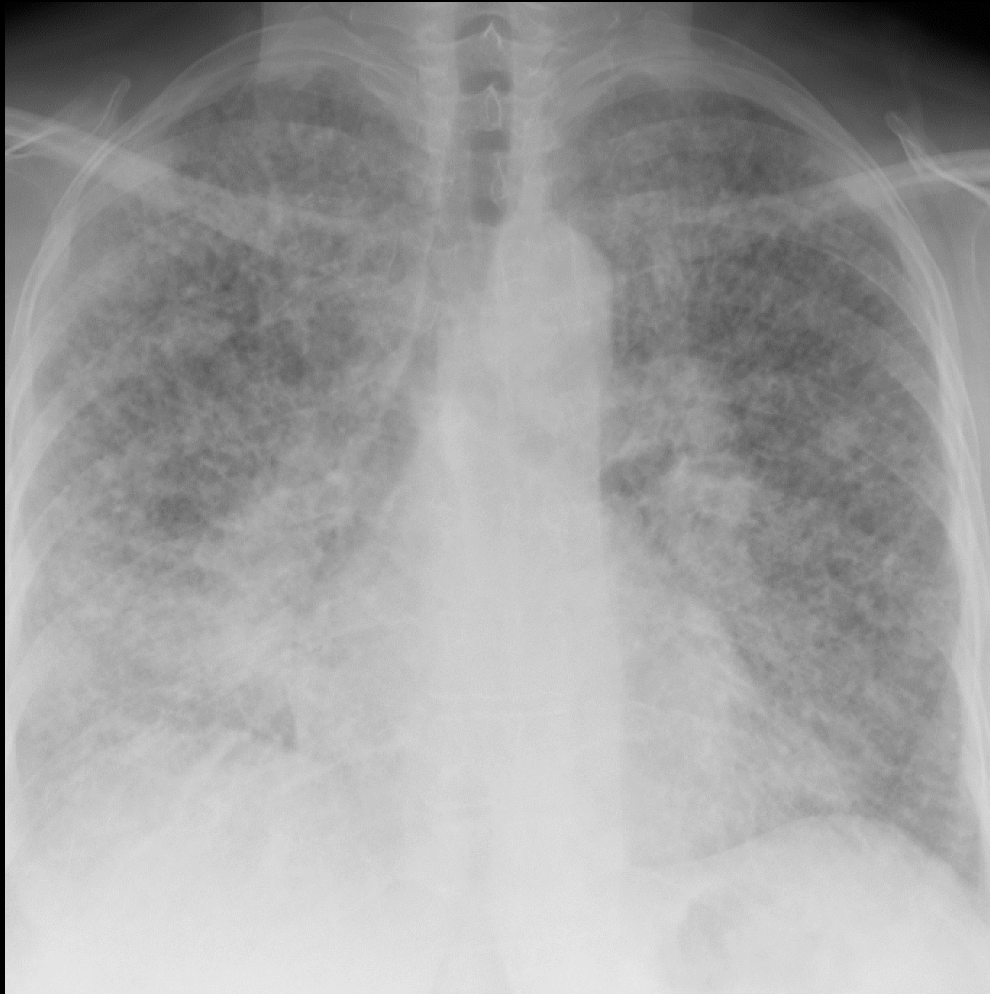
Chagas disease

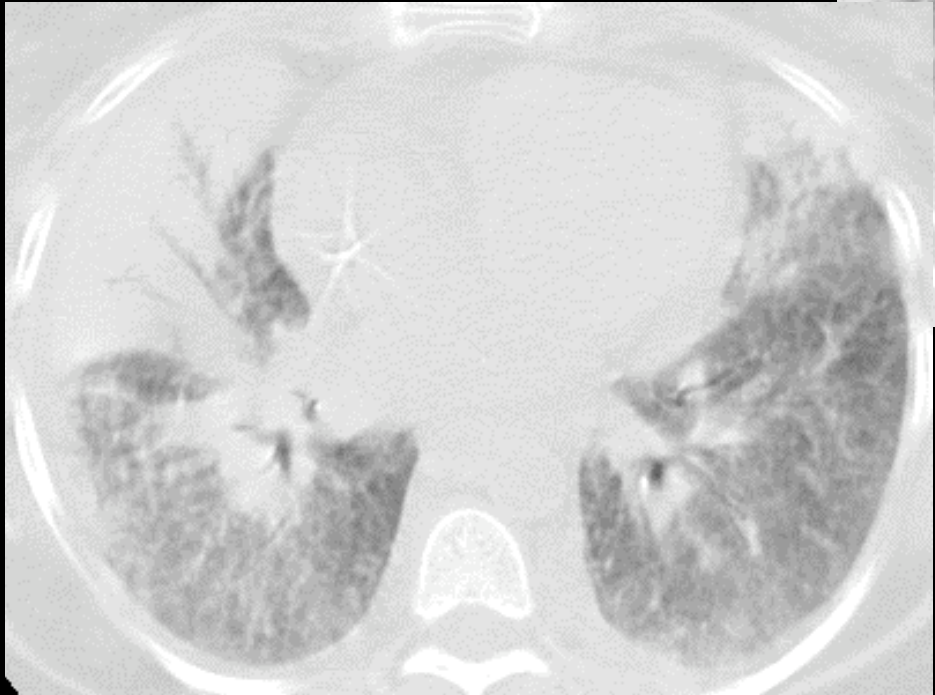

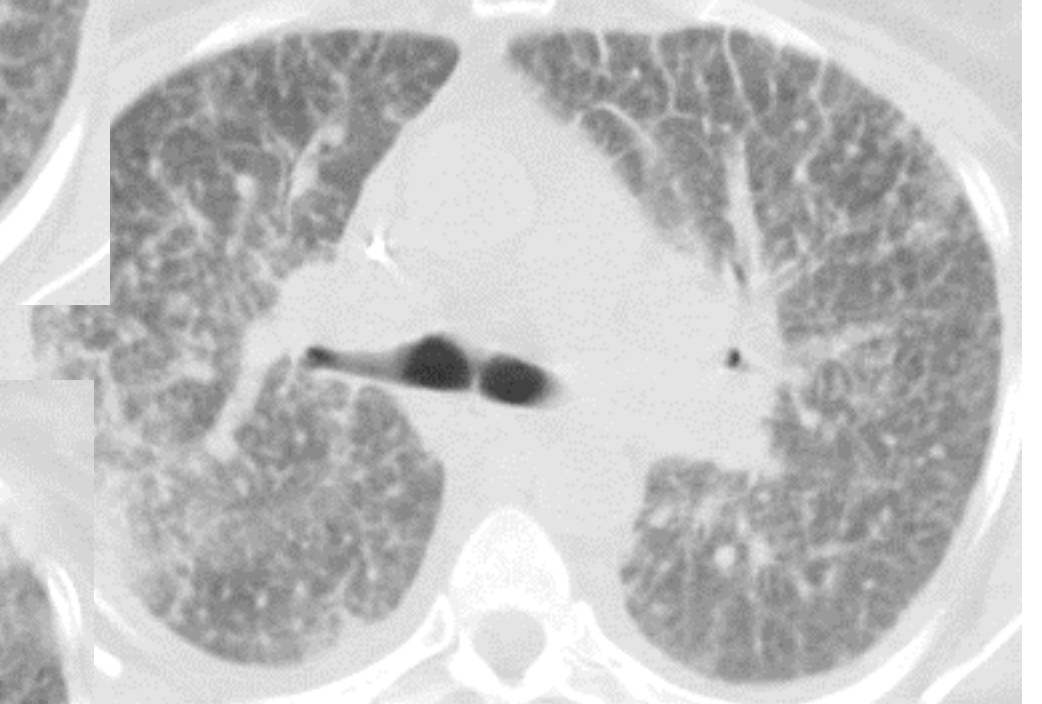

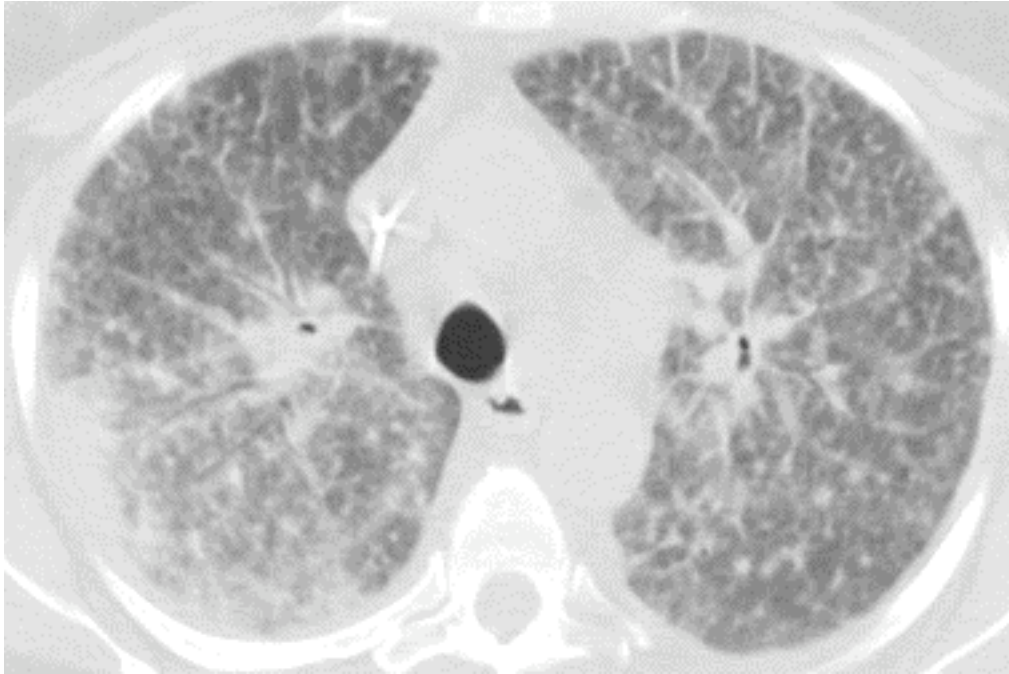
Unknown case 2

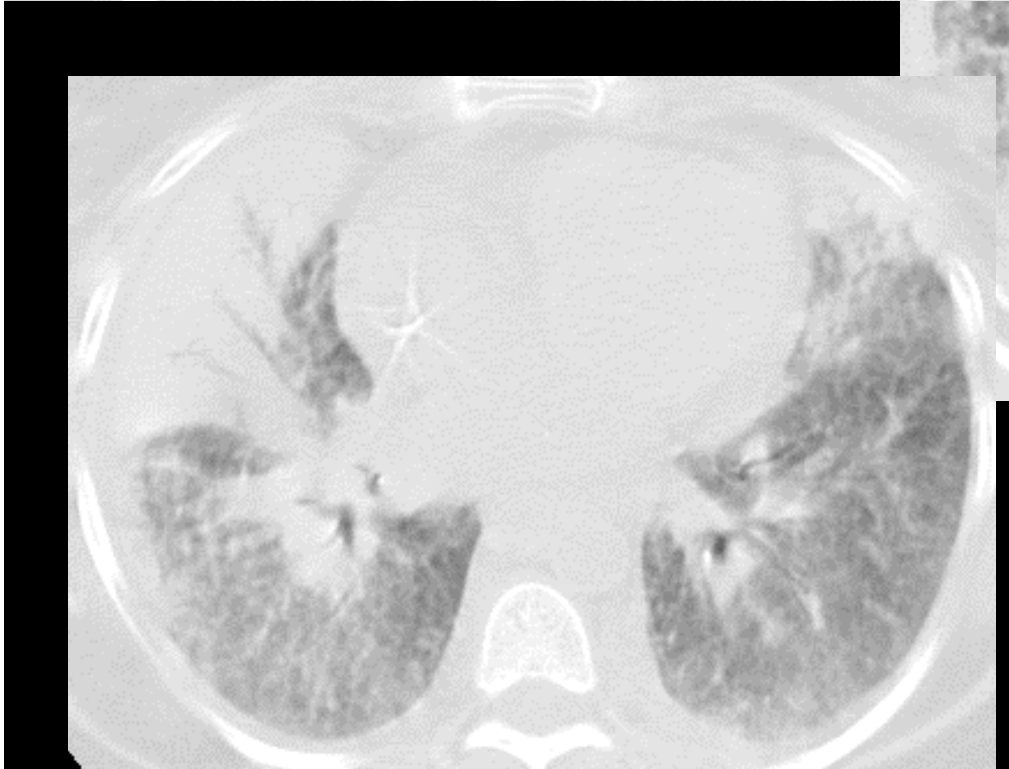
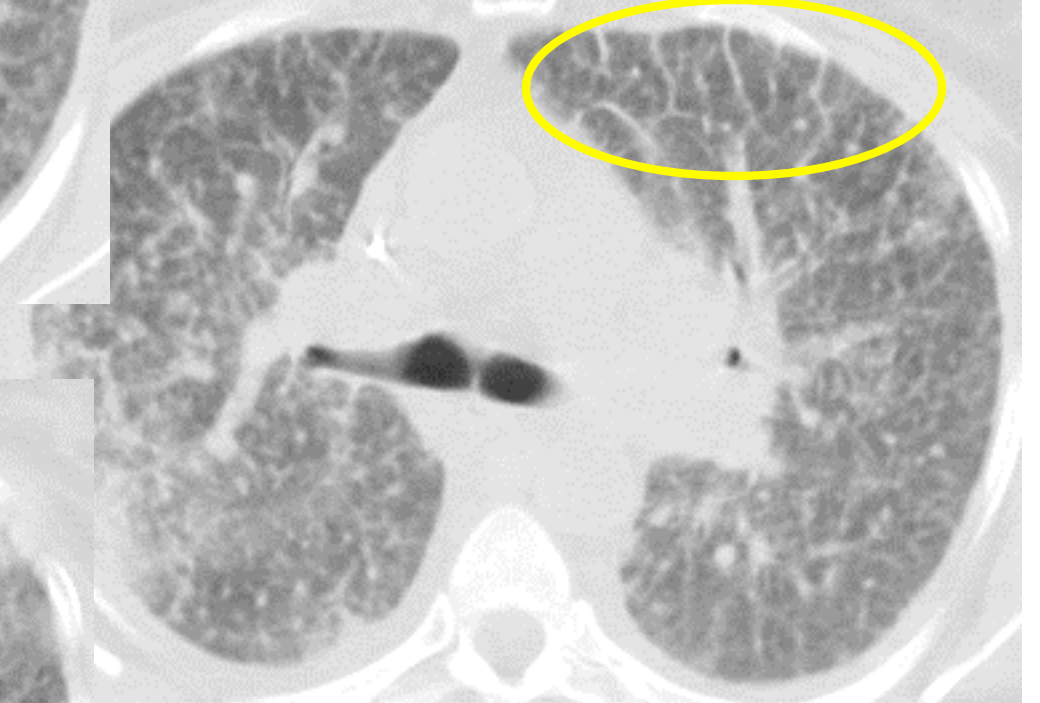
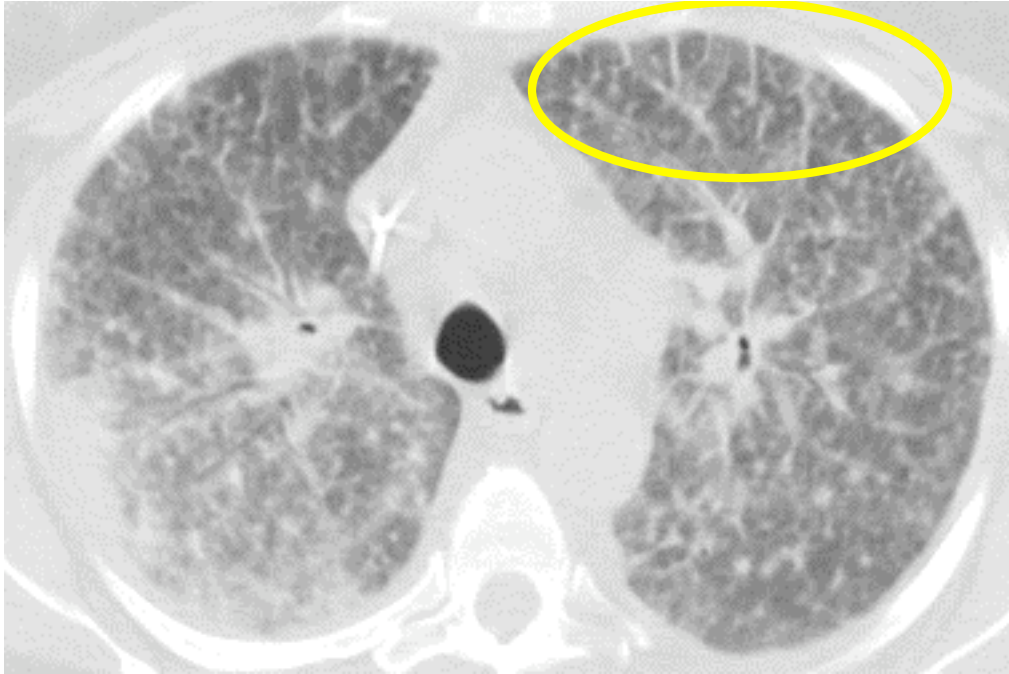
40 yo, dyspnea, anasarca


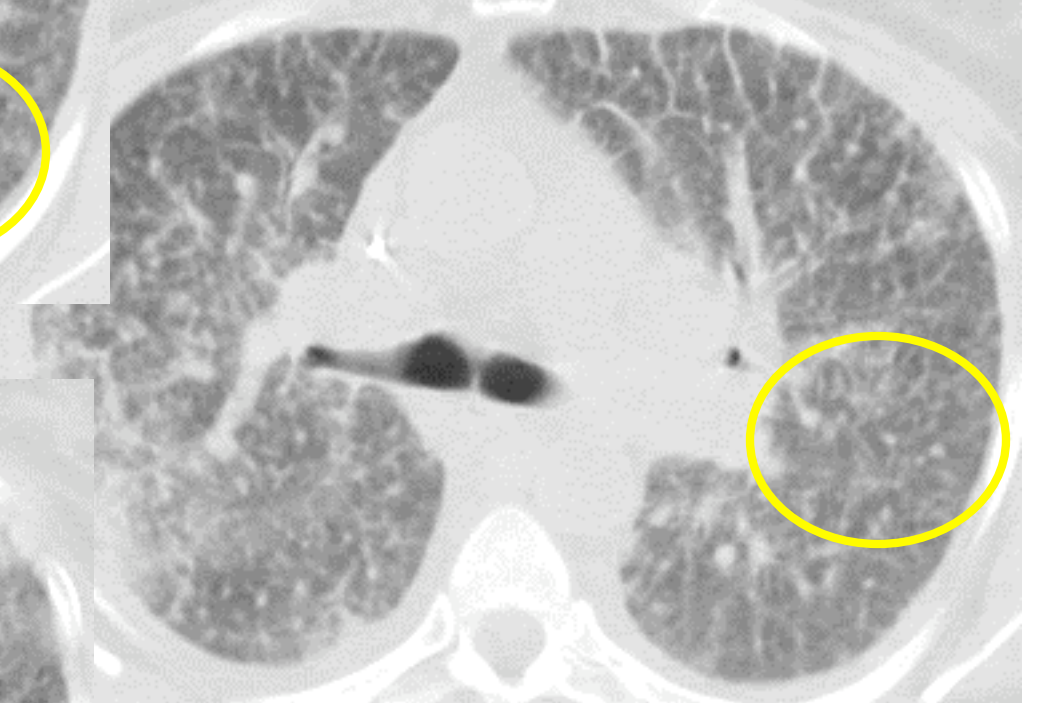
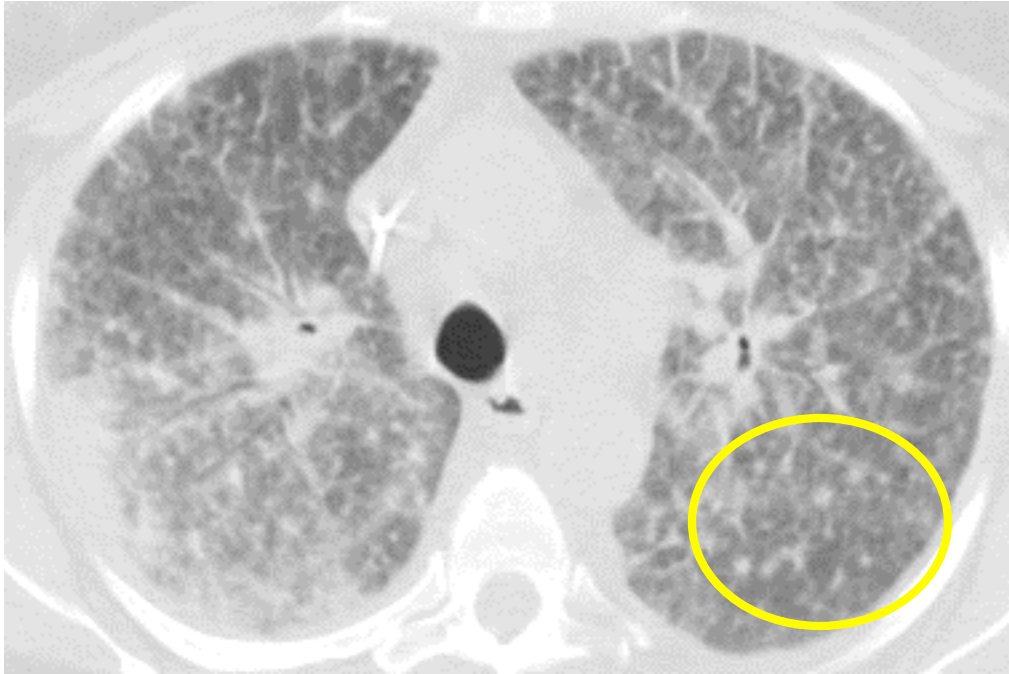


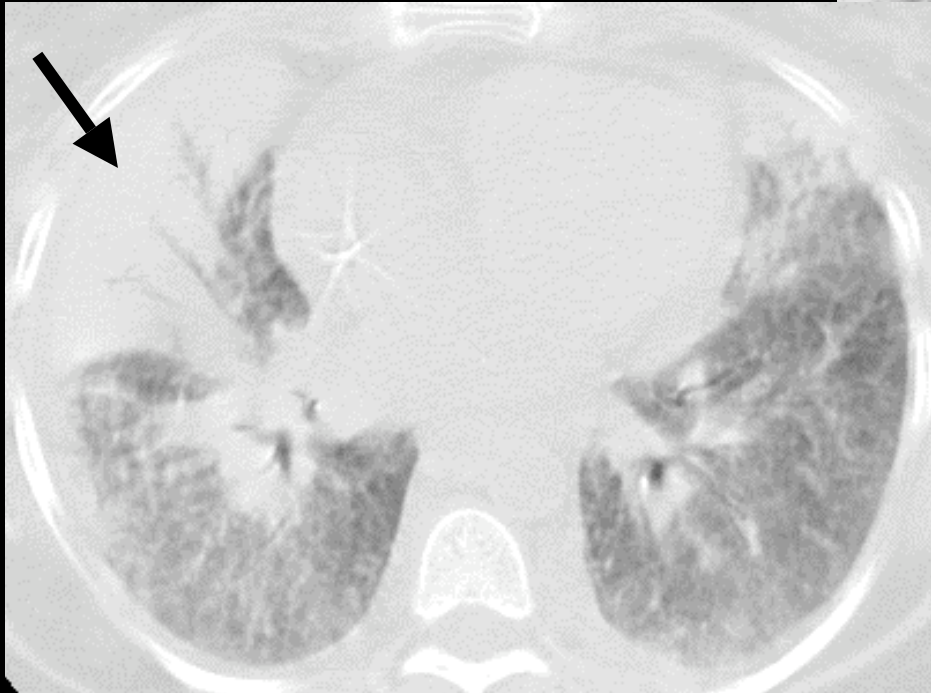

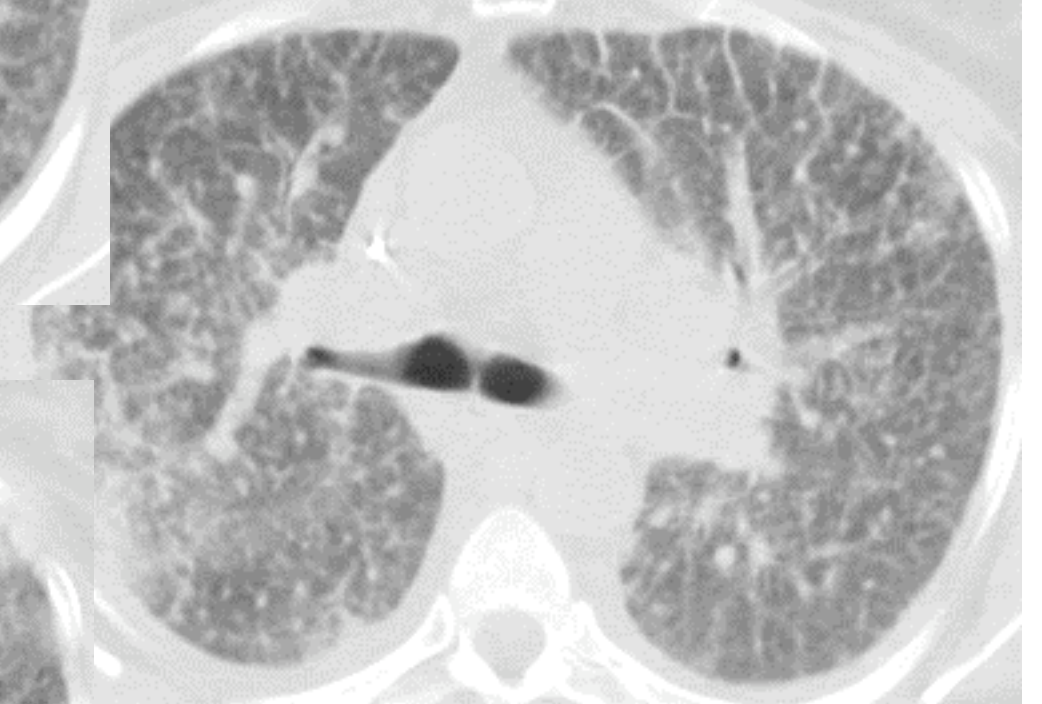

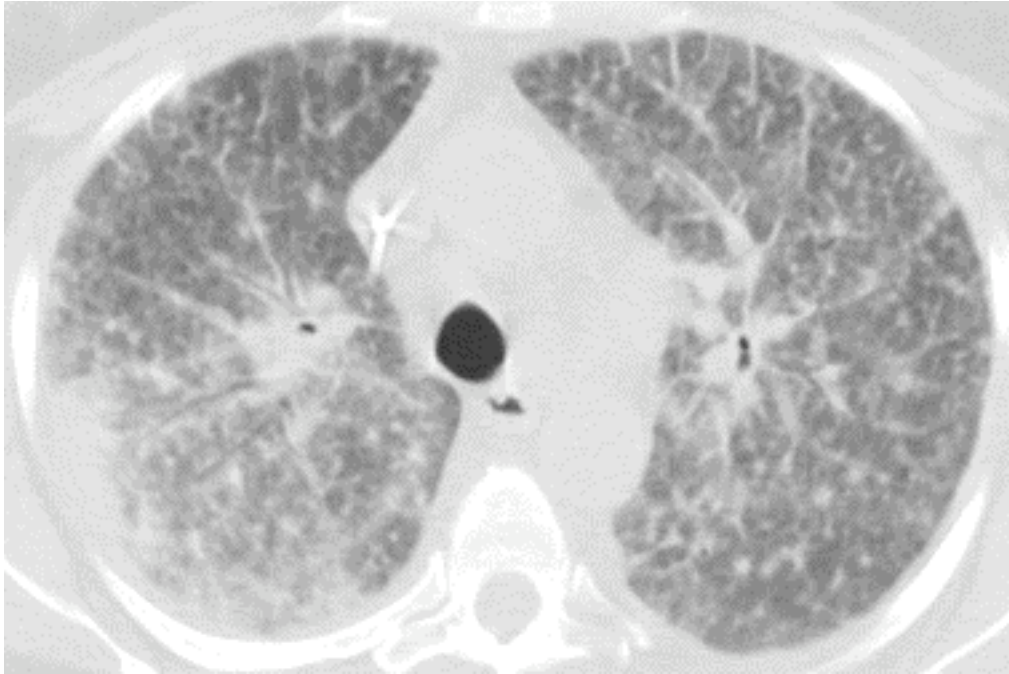
Bilateral reticulonodular; confluent opacity in RML

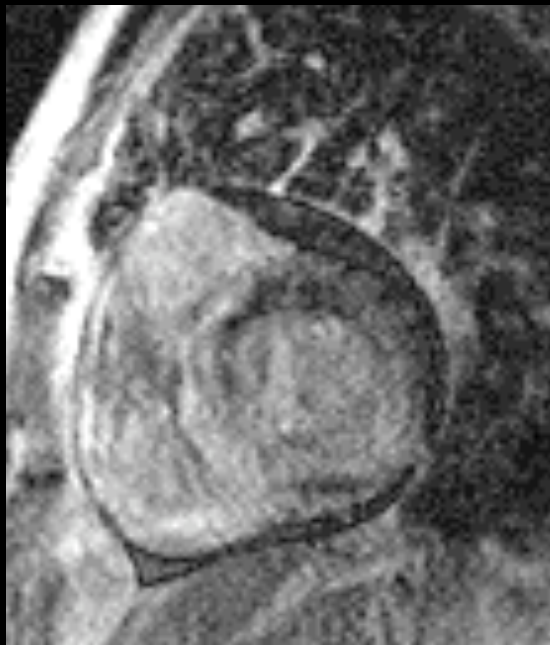
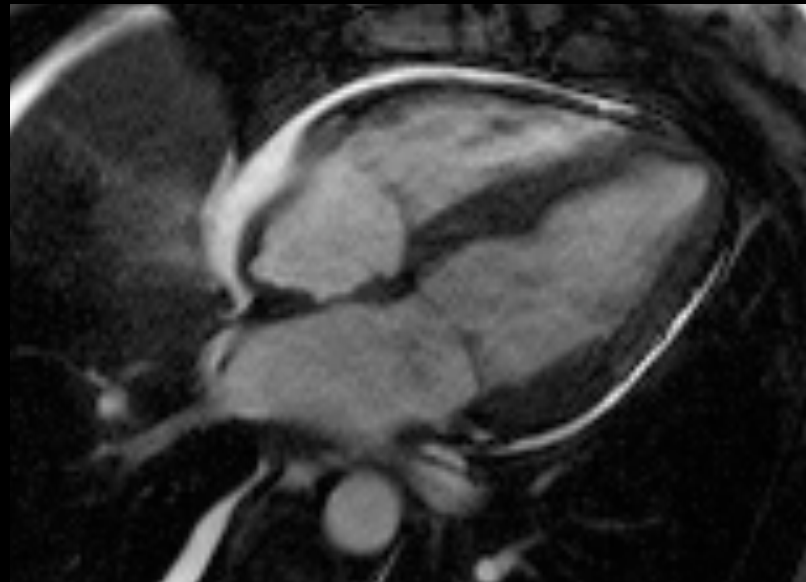
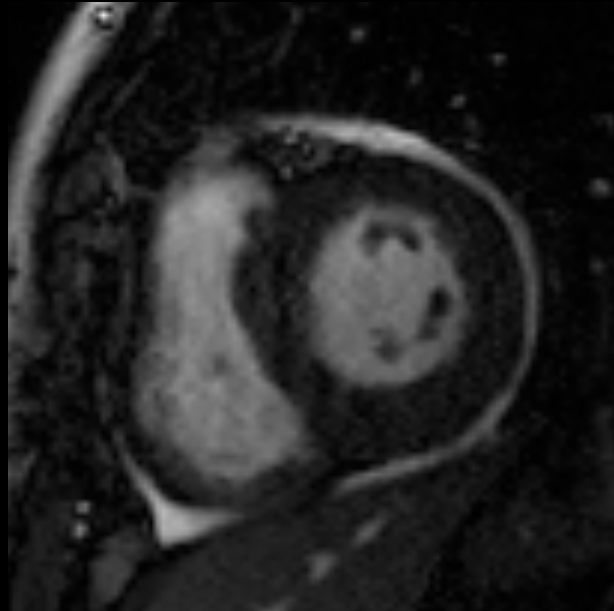




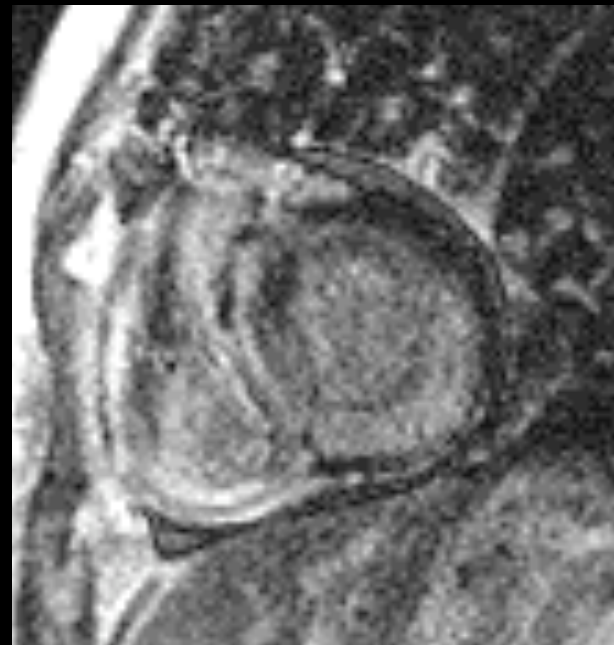




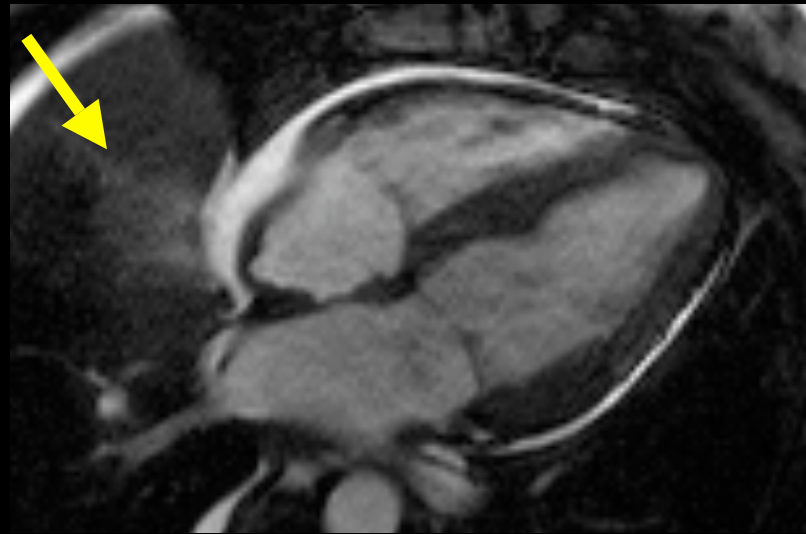
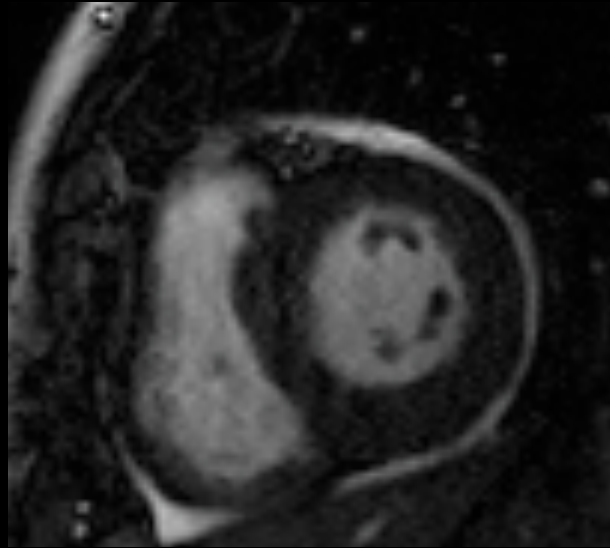




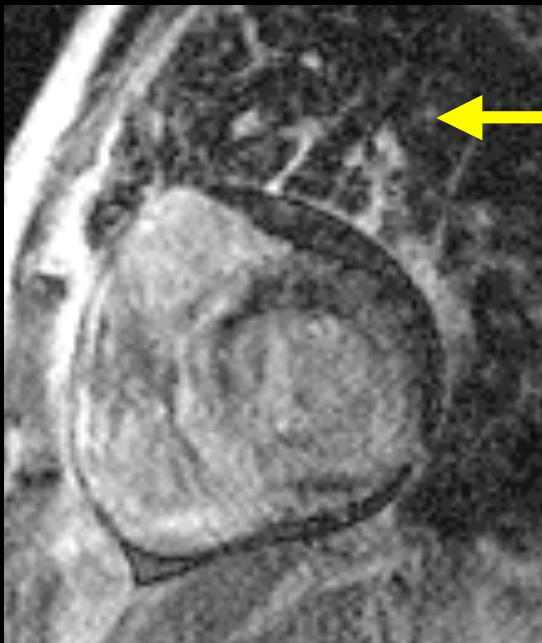DE



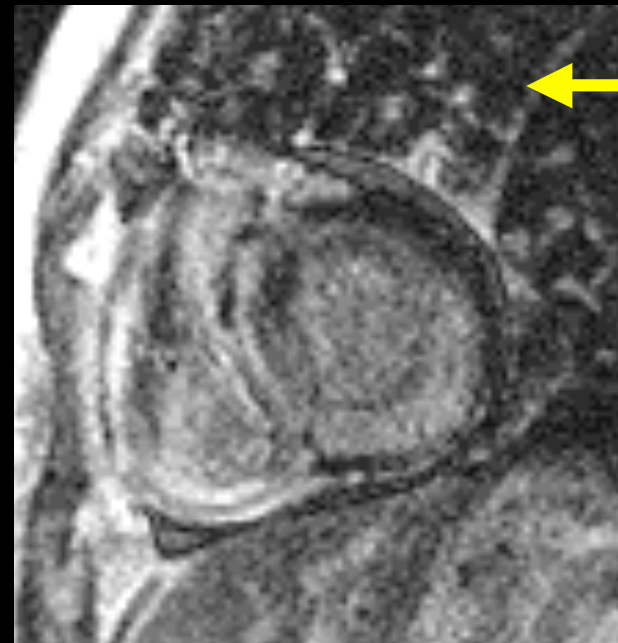
DE



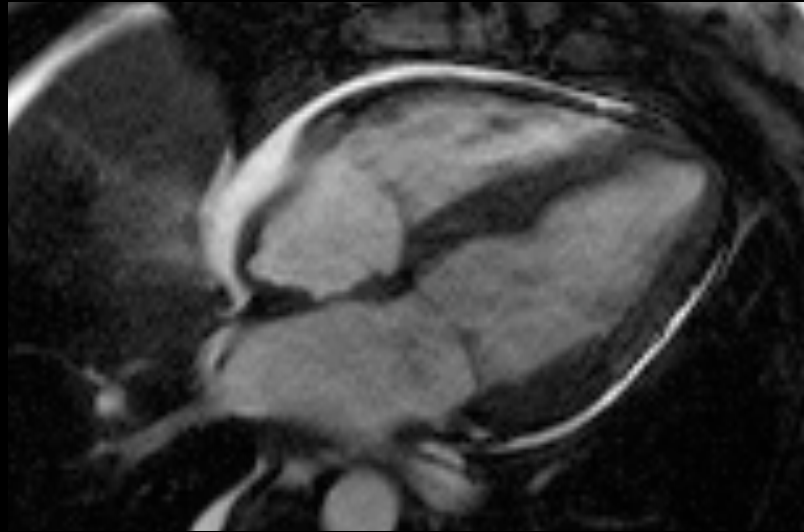
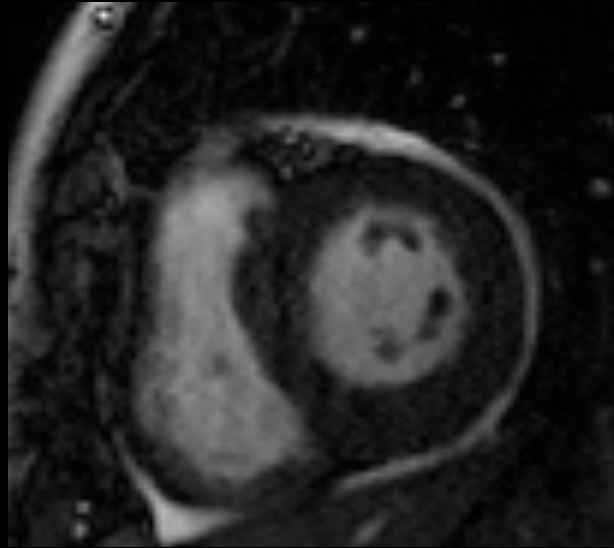
Abnormal lung signal



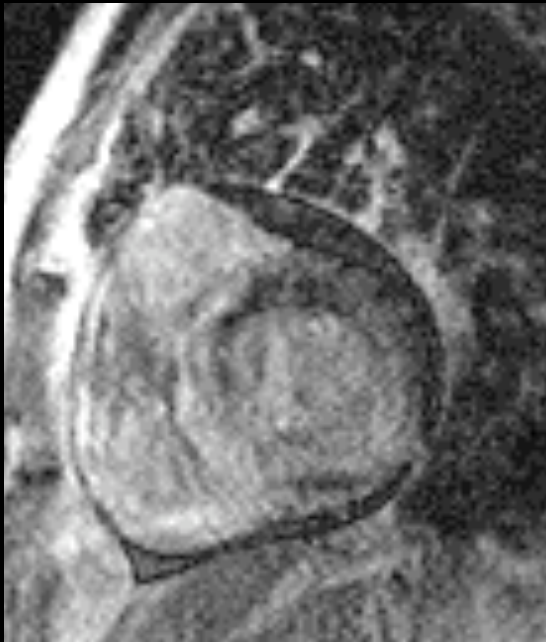DE



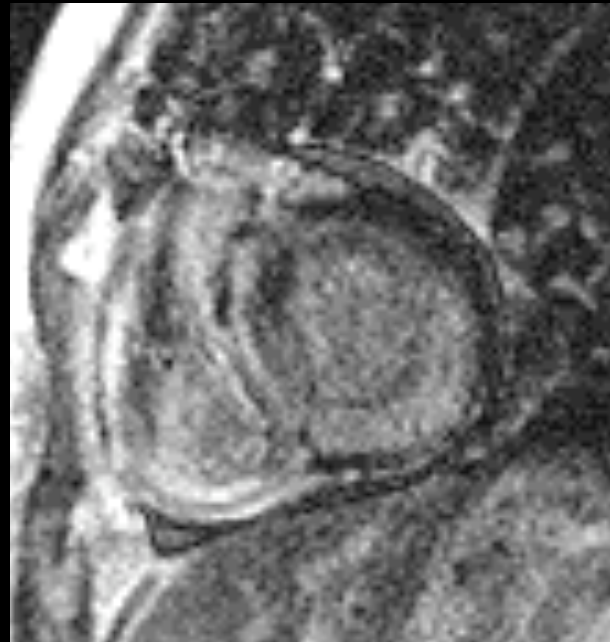
DE



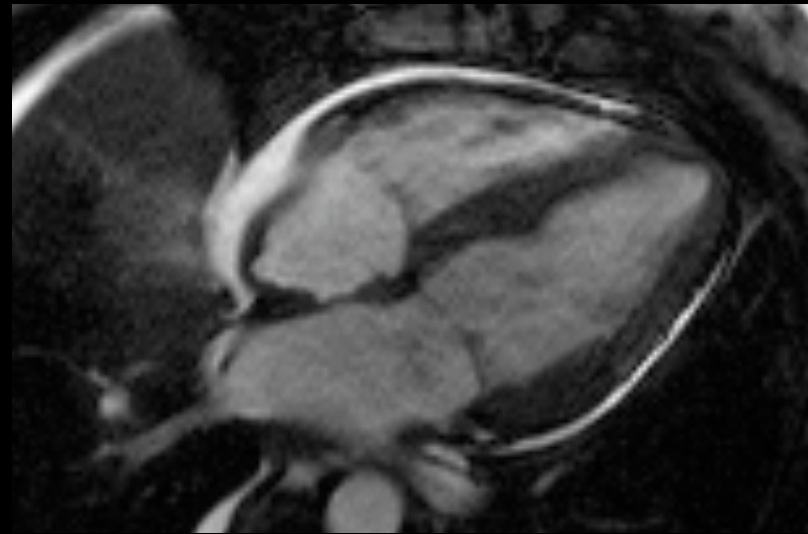
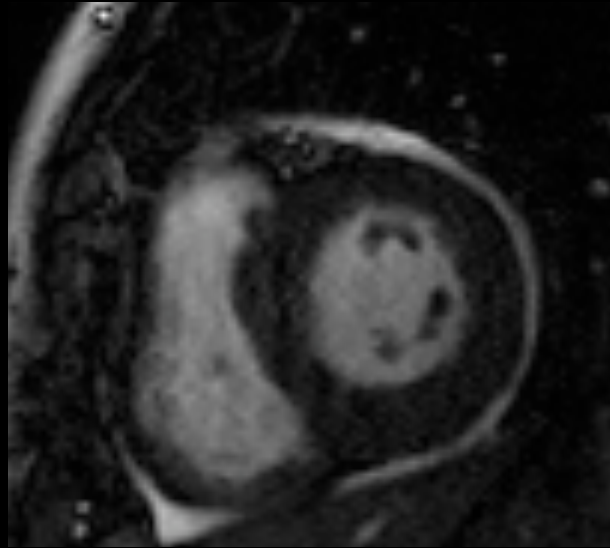
LV + RV hypertrophy



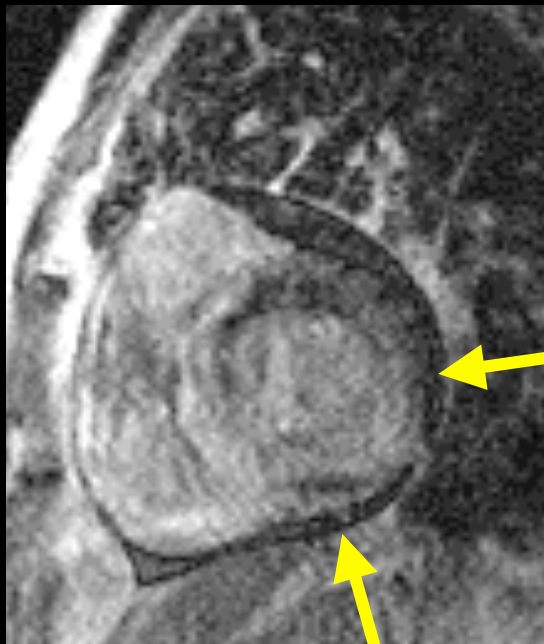
DE



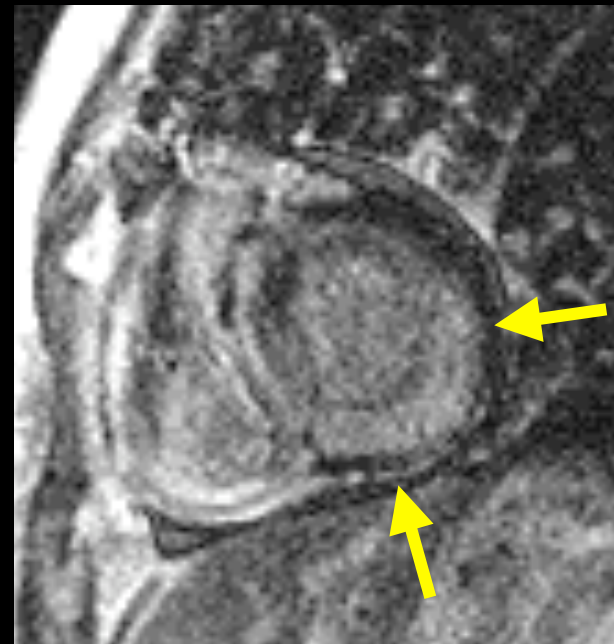
DE



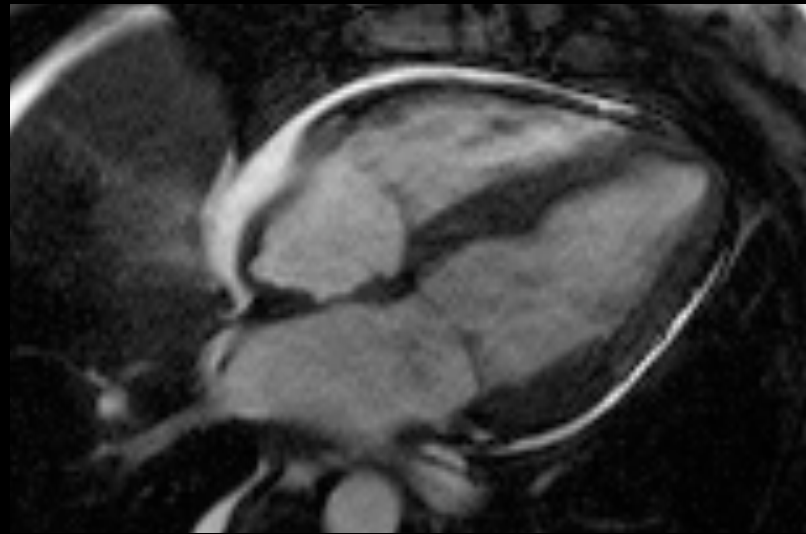
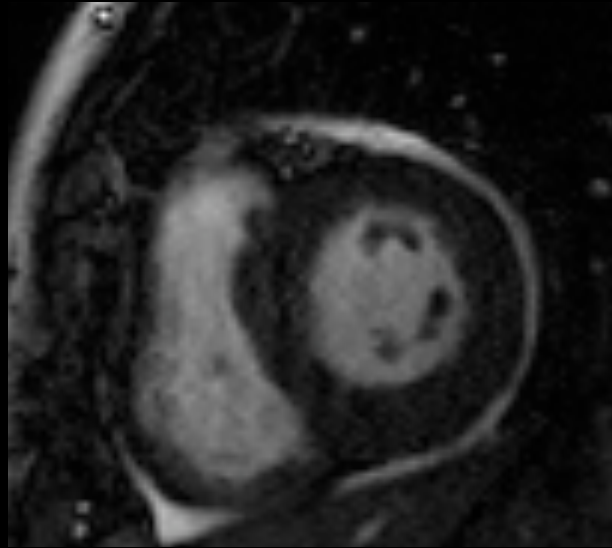
diffuse subendocardial DE



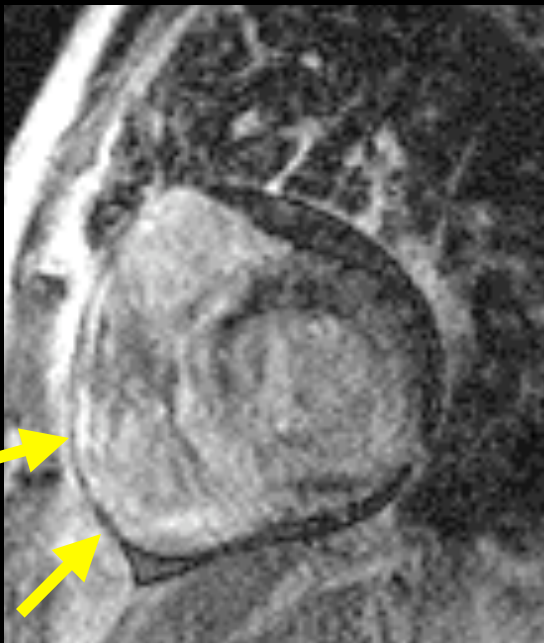DE



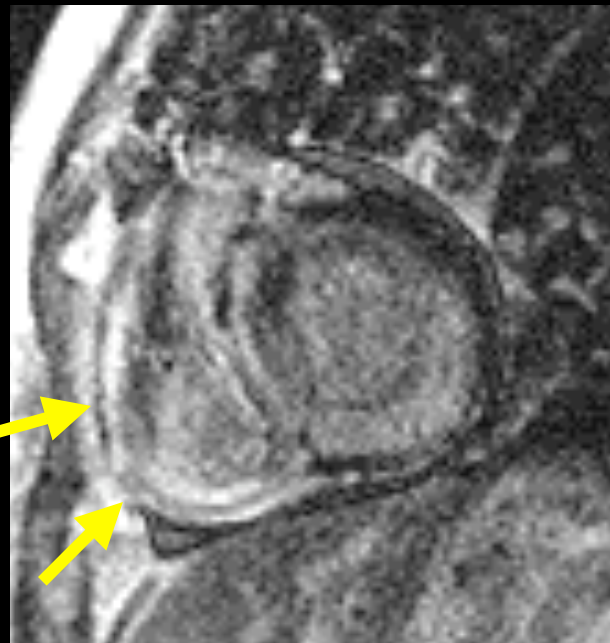
DE



RV enhancement



DE



DE

Amyloid

(pulmonary + cardiac)

Laura E. Heyneman, MD
heyne001@mc.duke.edu
www.radiologytalks.com